

Stereotactic radiosurgery XX: ocular neuromyotonia in association with gamma knife radiosurgery

W C Candy Sze¹, Joe McQuillan², P Nicholas Plowman³, Niall MacDougall³, Philip Blackburn⁴, H Ian Sabin⁴, Nadeem Ali² and William M Drake¹

¹Department of Endocrinology ²Department of Ophthalmology ³Department of Clinical Oncology
⁴Gamma Knife Unit, St Bartholomew's Hospital, London EC1A 7BE, UK

Correspondence
should be addressed
to W C C Sze
Email
candy.sze@bartshealth.nhs.uk

Summary

We report three patients who developed symptoms and signs of ocular neuromyotonia (ONM) 3–6 months after receiving gamma knife radiosurgery (GKS) for functioning pituitary tumours. All three patients were complex, requiring multi-modality therapy and all had received prior external irradiation to the sellar region. Although direct causality cannot be attributed, the timing of the development of the symptoms would suggest that the GKS played a contributory role in the development of this rare problem, which we suggest clinicians should be aware of as a potential complication.

Learning points:

- GKS can cause ONM, presenting as intermittent diplopia.
- ONM can occur quite rapidly after treatment with GKS.
- Treatment with carbamazepine is effective and improve patient's quality of life.

Background

Ocular neuromyotonia (ONM) is a rare diagnosis made clinically by the presence of intermittent diplopia after prolonged horizontal gaze in one direction. If present, the phenomenon usually lasts from seconds to minutes and occurs frequently throughout the day. ONM may be idiopathic, or due to compressive/inflammatory causes, but over half of the cases reported have been associated with conventional external irradiation of the sellar/parasellar region. The oculomotor nerve has been most frequently reported, followed by the abducens and then the trochlear nerves. To date, there has only been one other paper reporting this finding in the context of gamma knife radiosurgery (GKS) (1). Here, we report three more cases occurring in patients treated with GKS for complex secretory pituitary tumours.

Case presentation

Case 1

A 52-year-old woman was diagnosed and treated at the age of 25, for Cushing's disease consequent upon a corticotrope pituitary microadenoma, with three-field external beam pituitary radiation (45 Gy in 25 fractions) and bilateral adrenalectomy (currently on hydrocortisone 5 mg b.d. and fludrocortisone 50 µg o.d.). Nine years following initial treatment (aged 34), she had developed severe, progressive hyper-pigmentation (plasma adrenocorticotrophic hormone (ACTH) >2000 ng/l, normal 10–50), that persisted despite transphenoidal surgery at that time and a repeat operation 4 years later (aged 38) with the addition of stereotactic multi-arc radiotherapy (SMART) given (12.5 Gy) (2). Over the years, her

hyperpigmentation (Nelson's syndrome) continued and with the identification of a residual area of abnormal tissue in the right cavernous sinus (thought to be the source of the excessive ACTH secretion), she was treated with GKS to a dose of 22 Gy (maximum dose of 1.8 Gy to chiasm and 3.5 Gy to right optic nerve), 13 years after her SMART. Five months after GKS, there was biochemical improvement (plasma ACTH 1000 ng/l), but she complained of her right eye being intermittently 'stuck' on right lateral gaze. Her visual acuity and fields were unaffected immediately after GKS. Each episode lasted a few minutes and occurred several times a day. She could terminate the episodes by closing her eyes. She frequently woke with her right eye in a divergent position, typically for periods up to 30 min. On examination at rest, she had full ocular movements with no deviation. On prolonged right-sided gaze (at least 20 s), initially there was a slight right esotropia, which then became a small right exotropia with diplopia. This recovered spontaneously within 30 s. A diagnosis of ONM affecting the right lateral rectus was made and the patient was offered therapy with carbamazepine. This was declined as her symptoms were insufficiently troublesome and the episodes could be self-aborted (Table 1).

Case 2

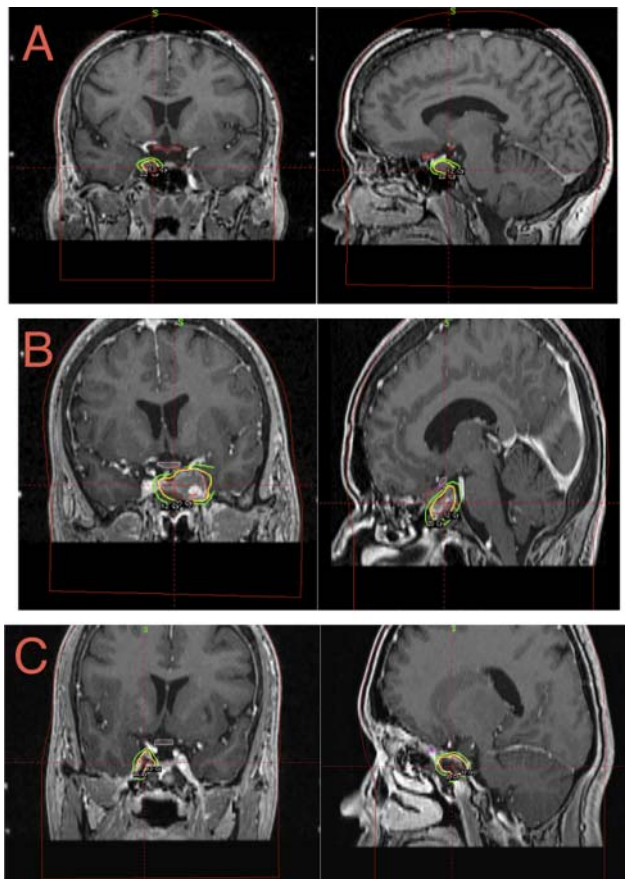
A 29-year-old woman was diagnosed with acromegaly due to a large somatotrope pituitary adenoma invading

surrounding structures. Her mean serum growth hormone (GH) and insulin-like growth factor 1 levels were 559 mU/l (safe level <5 mU/l) (3) and 1146 ng/ml (range 109–284 ng/ml, median 176) respectively. She underwent debulking transphenoidal surgery, followed by external pituitary irradiation (45 Gy in 25 fractions). High dose dopamine agonist and somatostatin analogue therapies were ineffective at controlling residual severe GH excess and so pegvisomant was commenced. Biochemical control was achieved at a dose of 25 mg daily, but treatment was complicated by severe injection site lipohypertrophy. She was treated with GKS a year later (20 Gy, maximum 5.4 Gy to the chiasm and 3.2 Gy to left optic nerve, Fig. 1B) to her residual tumour in the left cavernous sinus, with the specific aim of facilitating a reduction in the pegvisomant dose requirement. Six months after GKS, she complained of frequent episodes (up to ten times daily), of blurred vision and diplopia, with no previous reports of changes in visual acuity or fields pre- or post GKS. These occurred every morning and could be terminated by closing her left eye for 5 min. On examination at her first presentation, there was no manifest ocular deviation and full ocular ductions. However, following sustained left gaze, a moderate exotropia developed in the primary position with recovery after 30 s. She was diagnosed with ONM affecting the left lateral rectus. She was treated with carbamazepine 100 mg twice daily and, 2 months later, the episodes had reduced in frequency to one to two times

Table 1 Summary of the cases and treatment given.

Case	Age/sex	Diagnosis	Co-morbidities	Previous ocular history	Treatments received	Medical treatments received	Management
1	52/F	Cushing's disease (corticotrope pituitary microadenoma)	Right nephrectomy for RCC 1998 Thyroidectomy (for MNG) 1998 Hypertension T2DM AF	Iritis LASER refractive surgery 2008	EBRT 1983 Bilateral adrenalectomy 1983 TSS 1992, 1996 SMART 1996 GKS 2009 TSS 2007 EBRT 2008 GKS 2009	Octreotide, cabergoline	Conservative – declined carbamazepine
2	32/F	Acromegaly (somatotrope pituitary macroadenoma)				Octreotide, pegvisomant	Carbamazepine continued for 33 months Definite initial improvement with complete resolution of symptoms
3	42/F	Cushing's disease (invasive corticotrope pituitary macroadenoma)			TSS 2008 EBRT 2008 GKS 2011	Lomustine and capecitabine (one cycle), temozolamide (six cycles)	Carbamazepine for <1 month

F, female; RCC, renal cell carcinoma; MNG, multinodular goiter; T2DM, type 2 diabetes mellitus; AF, atrial fibrillation; EBRT, external beam radiotherapy; TSS, transphenoidal surgery; SMART, stereotactic multi-arc radiotherapy; GKS, gamma knife surgery.

**Figure 1**

Planning gamma knife MRI. (A) GKS given at a dose of 22 Gy to the 50% isodose, covering 95% of a 0.71cc lesion. Chiasm received 1.8 Gy and right optic nerve 3.5 Gy. (B) GKS given at a dose of 20 Gy to the 47% isodose, covering 86% of a 7.7cc lesion. Dose to chiasm restricted to 5.4 Gy and left optic nerve 3.2 Gy. (C) GKS given at a dose of 20 Gy to the 53% isodose, covering 92% of a 1.1cc lesion. Dose to chiasm restricted to 3.9 Gy and right optic nerve 3.7 Gy.

weekly. When last assessed, 4 years after GKS, the symptoms had completely resolved.

Case 3

A 38-year-old woman with a large, invasive corticotrope macroadenoma and severe clinical Cushing's disease underwent debulking trans-sphenoidal surgery followed by external beam irradiation (45 Gy in 25 fractions). Residual hypercortisolaemia was successfully treated with metyrapone and her symptoms and physical signs of cortisol excess resolved. Two years after her original surgery, severe cortisol excess recurred, in association with re-growth of her pituitary tumour, invading into and through the right cavernous sinus. Lomustine and capecitabine

chemotherapy was commenced, with a good radiological response, but she developed hand/foot syndrome after one cycle. Treatment was switched to temozolamide and she completed six cycles of therapy. Substantial radiological shrinkage was observed in association with an improvement in cortisol hypersecretion, allowing cessation of metyrapone therapy. Residual tumour in the right cavernous sinus (Fig. 1C) was treated with GKS, receiving 20 Gy (maximum dose of 3.9 Gy to the chiasm and 3.7 Gy to the right optic nerve), with no immediate effects on her visual acuity or fields. Three months after GKS, she complained of new intermittent, short-lived blurred vision after prolonged right gaze due to intermittent horizontal diplopia. She also had these symptoms on waking which settled after 5–10 min. On examination, following prolonged right gaze, she developed a small right exotropia in the primary position with recovery after 15 s. A diagnosis of ONM was made, affecting the right lateral rectus. She was treated with carbamazepine 100 mg b.d. with symptomatic improvement, and subsequently discontinued after 3 months of her own accord as the symptoms became progressively less troublesome.

Discussion

In this report, we describe a series of three patients in whom a clinical diagnosis of ONM was made 3–6 months following delivery of GKS to the sellar/parasellar region. To our knowledge, there has only been one previous report of ONM following GKS in a similar clinical context (1). In addition to surgery (and in one case chemotherapy), all three of our cases had also been previously treated, 2–17 years earlier, with conventional external beam pituitary irradiation, which is well-documented as being associated with the development of ONM. It is therefore possible that ONM in our cases was as a result of this prior external beam irradiation. However, the timing of the onset so soon after GKS in this case series raises the possibility of an etiological role for GKS in ONM. All our patients would have received a cumulative dose of 52 Gy or less, which is the tolerance dose set in our centre.

The first description of a patient with probable ONM was in 1966, although it was not till 1970 that the term was first used. The postulated mechanisms of ONM are thought to include one or more of: ephaptic neural transmission leading to uncontrolled firing of nervous fibres within cranial nerves, with contractions outweighing relaxation; aberrant regeneration or re-organisation of a partially damaged nerve; or abnormal excitability due to a disorder of cell membrane potassium channels leading to neuro-myotonic discharges (4). Knowledge of the pathogenesis



was the reason for the empirical use of carbamazepine therapy (as a membrane stabilizing agent) in two patients, although offered to all three. In the absence of an understanding of the natural history of GKS-associated ONM, no firm conclusions about the efficacy of carbamazepine can be drawn and carbamazepine has never been used as a pretreatment to prevent ONM in any centres that we are aware of. However, its use was temporally associated with symptomatic improvement in both patients and it seems reasonable to offer carbamazepine to similar patients in the future once diagnosis is reached.

The prevalence of ONM is difficult to quantify as many are reported as cases (over 40 cases and the majority of them following conventional radiotherapy and only three cases following GKS). The prevalence of radiation induced optic neuropathy has been reported from 0 to 0.19% after a single dose of 10 Gy given as GKS but they were not specific to pituitary tumours alone. For pituitary tumours alone (both functioning and non functioning), it showed a 4% incidence at a much lower dose given at 3.1 Gy (5). The difference in the radiosensitivity of oculomotor nerves and the anterior visual pathway may be due to the radiosensitivity of the nerve fibres itself, where sensory nerves (optic) are the most sensitive to radiation followed by somatic nerves and motor nerves (oculomotor) being most resistant (6).

Reporting bias is an inherent limitation of a case series such as this. These patients represent ~2% of the cohort of patients treated at our institution for pituitary tumours with stereotactic radiotherapy, by one of linear accelerator, gamma knife or cyberknife. As previously reported (2), our policy has been largely to reserve this modality of treatment for patients with refractory disease despite the prior use of external beam irradiation. As such, our cohort of patients treated with stereotactic radiotherapy could be considered to be 'enriched' with potential 'candidates' for ONM, whereas other studies have a mix of patients who may or may not have been exposed to other forms of radiation previously. Furthermore, once one case in a unit has been identified, clinicians are alerted to look for similar findings in other patients with similar symptoms.

It is difficult to directly compare the efficacy of the different modalities of treatment for our centre as GKS is primarily used as a salvage treatment. As a result of this, we accept that there is the potential for a higher risk of damage but our patients were severely affected by their hormonal excess and required intervention in an attempt to improve their quality of life. We do not wish to deter centres from performing GKS as this is a very important tool

when repeat surgery or conventional radiotherapy is not possible. We wish to raise the awareness of the diagnosis of ONM in patients treated with GKS so that effective treatment for ONM can be offered to patients promptly.

Looking at recurrences only, the remission rate following surgery has been reported to be about 60% for acromegaly and 46% for Cushing's disease, along with post operative complications of diabetes insipidus and cerebrospinal fluid (CSF) leak in as much as 50% of patients (7)(8). Castinetti *et al.* (9) reports the use of GKS achieving a remission rate of 44.7% with mean time to remission being 42.6 months and hypopituitarism induced in 23% of patients. Using conventional radiotherapy can take 5–10 years for hormonal control but the control can be achieved in 50–90% of patients (dependent on which tumour) and 13–56% of patients will develop hypopituitarism following treatment (10). However, we do need to take each patient individually to assess what treatment is most suitable, not forgetting the availability of drugs for hormone control but the three patients we have discussed have failed other modalities of treatment including medical and in a highly complex situation, we would expect more side effects.

In reporting this case series, we do not aim to dissuade clinicians from deploying GKS. Rather, we hope to encourage colleagues working in other GKS units, particularly those who employ this modality of therapy without prior external irradiation, to consider this diagnosis in patients who complain of transient blurring or diplopia and to obtain formal orthoptic confirmation of the diagnosis (as in our cases).

In addition, we would urge colleagues to report any cases (or absence of cases in large series) in the peer-reviewed literature, in order to establish a more accurate assessment of how frequently this phenomenon occurs in patients treated for complex pituitary disease as well as long term outcomes.

Declaration of interest

The authors declare that there is no conflict of interest that could be perceived as prejudicing the impartiality of the research reported.

Funding

This research did not receive any specific grant from any funding agency in the public, commercial or not-for-profit sector.

Patient consent

Patients have given consent previously on a different consent form, which is enclosed.



Author contribution statement

W M Drake and W C C Sze were involved with overall patient care and reporting of these cases. J McQuillan and N Ali were involved in the ophthalmology workup and treatment of ONM. P N Plowman, P Blackburn and H I Sabin were involved in of the administration of gammaknife radiosurgery. N MacDougal retrieved information of previous radiation and calculation of cumulative doses.

References

- 1 Much JW, Weber ED & Newman SA 2009 Ocular neuromyotonia after gamma knife stereotactic radiation therapy. *Journal of Neuro-Ophthalmology* **29** 136–139. (doi:10.1097/WNO.0b013e3181a57d19)
- 2 Swords FM, Allan CA, Plowman PN, Sibtain A, Evanson J, Chew SL, Grossman AB, Besser GM & Monson JP 2003 Stereotactic radiosurgery XVI: a treatment for previously irradiated pituitary adenomas. *Journal of Clinical Endocrinology and Metabolism* **88** 5334–5340. (doi:10.1210/jc.2002-020356)
- 3 Orme SM, McNally RJ, Cartwright RA & Belchetz PE 1998 Mortality and cancer incidence in acromegaly: a retrospective cohort study. United Kingdom Acromegaly Study Group. *Journal of Clinical Endocrinology and Metabolism* **83** 2730–2734. (doi:10.1210/jcem.83.8.5007)
- 4 Plant GT 2006 Putting ocular neuromyotonia in context. *Journal of Neuro-Ophthalmology* **26** 241–243. (doi:10.1097/01.wno.0000249328.42357.0e)
- 5 Astradsson A, Wiencke AK, Munck af Rosenschold P, Engelholm SA, Ohlhues L, Roed H & Juhler M 2014 Visual outcome after fractionated stereotactic radiation therapy of benign anterior skull base tumors. *Journal of Neuro-Oncology* **118** 101–108. (doi:10.1007/s11060-014-1399-0)
- 6 Santacrose A, Kamp MA, Budach W & Hänggi D 2013 Radiobiology of radiosurgery for the central nervous system. *BioMed Research International* **2013** Article ID: 362761. (doi:10.1155/2013/362761)
- 7 Yamada S, Fukuhara N, Oyama K, Takeshita A & Takeuchi Y 2010 Repeat transsphenoidal surgery for the treatment of remaining or recurring pituitary tumors in acromegaly. *Neurosurgery* **67** 949–956. (doi:10.1227/NEU.0b013e3181ec4379)
- 8 Valderrábano P, Aller J, Garcia-Valdecasas L, Garcia-Uria J, Martin L, Palacios N & Estrada J 2014 Results of repeated transsphenoidal surgery in Cushing's disease. Long-term follow-up. *Endocrinología y Nutrición* **61** 176–183. (doi:10.1016/j.endonu.2013.10.008)
- 9 Castinetti F, Nagai M, Morange I, Dufour H, Caron P, Chanson P, Cortet-Rudelli C, Kuhn JM, Conte-Devolx B, Regis J *et al.* 2009 Long-term results of stereotactic radiosurgery in secretory pituitary adenomas. *Journal of Clinical Endocrinology and Metabolism* **94** 3400–3407. (doi:10.1210/jc.2008-2772)
- 10 Becker G, Kocher M, Kortmann RD, Paulsen F, Jeremic B, Müller RP & Bamberg M 2002 Radiation therapy in the multimodal treatment approach of pituitary adenoma. *Strahlentherapie und Onkologie* **178** 173–186. (doi:10.1007/s00066-002-0826-x)

Received in final form 12 November 2014

Accepted 4 August 2015