

# Transient diabetes insipidus in pregnancy

Pedro Marques<sup>1,2</sup>, Kavinga Gunawardana<sup>2</sup> and Ashley Grossman<sup>2</sup>

<sup>1</sup>Endocrinology Department, Instituto Português de Oncologia de Lisboa, Francisco Gentil, Rua Professor Lima Basto, 1099-023 Lisboa, Portugal

<sup>2</sup>Oxford Centre for Diabetes, Endocrinology and Metabolism, University of Oxford, Oxford, UK

Correspondence  
should be addressed  
to P Marques  
**Email**  
pedro.miguel.sousa.  
marques@gmail.com

## Summary

Gestational diabetes insipidus (DI) is a rare complication of pregnancy, usually developing in the third trimester and remitting spontaneously 4–6 weeks *post-partum*. It is mainly caused by excessive vasopressinase activity, an enzyme expressed by placental trophoblasts which metabolises arginine vasopressin (AVP). Its diagnosis is challenging, and the treatment requires desmopressin. A 38-year-old Chinese woman was referred in the 37th week of her first single-gestation due to polyuria, nocturia and polydipsia. She was known to have gestational diabetes mellitus diagnosed in the second trimester, well-controlled with diet. Her medical history was unremarkable. Physical examination demonstrated decreased skin turgor; her blood pressure was 102/63 mmHg, heart rate 78 beats/min and weight 53 kg (BMI 22.6 kg/m<sup>2</sup>). Laboratory data revealed low urine osmolality 89 mOsmol/kg (350–1000), serum osmolality 293 mOsmol/kg (278–295), serum sodium 144 mmol/l (135–145), potassium 4.1 mmol/l (3.5–5.0), urea 2.2 mmol/l (2.5–6.7), glucose 3.5 mmol/l and HbA1c 5.3%. Bilirubin, alanine transaminase, alkaline phosphatase and full blood count were normal. The patient was started on desmopressin with improvement in her symptoms, and normalisation of serum and urine osmolality (280 and 310 mOsmol/kg respectively). A fetus was delivered at the 39th week without major problems. After delivery, desmopressin was stopped and she had no further evidence of polyuria, polydipsia or nocturia. Her sodium, serum/urine osmolality at 12-weeks *post-partum* were normal. A pituitary magnetic resonance imaging (MRI) revealed the neurohypophyseal T1-bright spot situated ectopically, with a normal adenohypophysis and infundibulum. She remains clinically well, currently breastfeeding, and off all medication. This case illustrates some challenges in the diagnosis and management of transient gestational DI.

## Learning points:

- Gestational DI is a rare complication of pregnancy occurring in two to four out of 100 000 pregnancies. It usually develops at the end of the second or third trimester of pregnancy and remits spontaneously 4–6 weeks after delivery.
- Gestational DI occurrence is related to excessive vasopressinase activity, an enzyme expressed by placental trophoblasts during pregnancy, which metabolises AVP. Its activity is proportional to the placental weight, explaining the higher vasopressinase activity in third trimester or in multiple pregnancies.
- Vasopressinase is metabolised by the liver, which most likely explains its higher concentrations in pregnant women with hepatic dysfunction, such acute fatty liver of pregnancy, HELLP syndrome, hepatitis and cirrhosis. Therefore, it is important to assess liver function in patients with gestational DI, and to be aware of the risk of DI in pregnant women with liver disease.
- Serum and urine osmolality are essential for the diagnosis, but other tests such as serum sodium, glucose, urea, creatinine, liver function may be informative. The water deprivation test is normally not recommended during pregnancy because it may lead to significant dehydration, but a pituitary MRI should be performed at some point to exclude lesions in the hypothalamo-pituitary region.
- These patients should be monitored for vital signs, fluid balance, body weight, fetal status, renal and liver function, and treated with desmopressin. The recommended doses are similar or slightly higher than those recommended for central DI in non-pregnant women, and should be titrated individually.

## Background

Gestational diabetes insipidus (DI) is a rare complication of pregnancy, estimated to occur in about two to four of every 100 000 pregnancies. The onset of gestational DI is usually in the third trimester of pregnancy, and it is characterised by the presence of hypotonic polyuria, polydipsia and excessive thirst (1). Transient gestational DI is associated with diagnostic and therapeutic challenges (1) (2). This report aims to describe one patient with transient gestational DI and reviews the pathophysiology, clinical manifestations, diagnosis and management of this uncommon condition.

## Case presentation

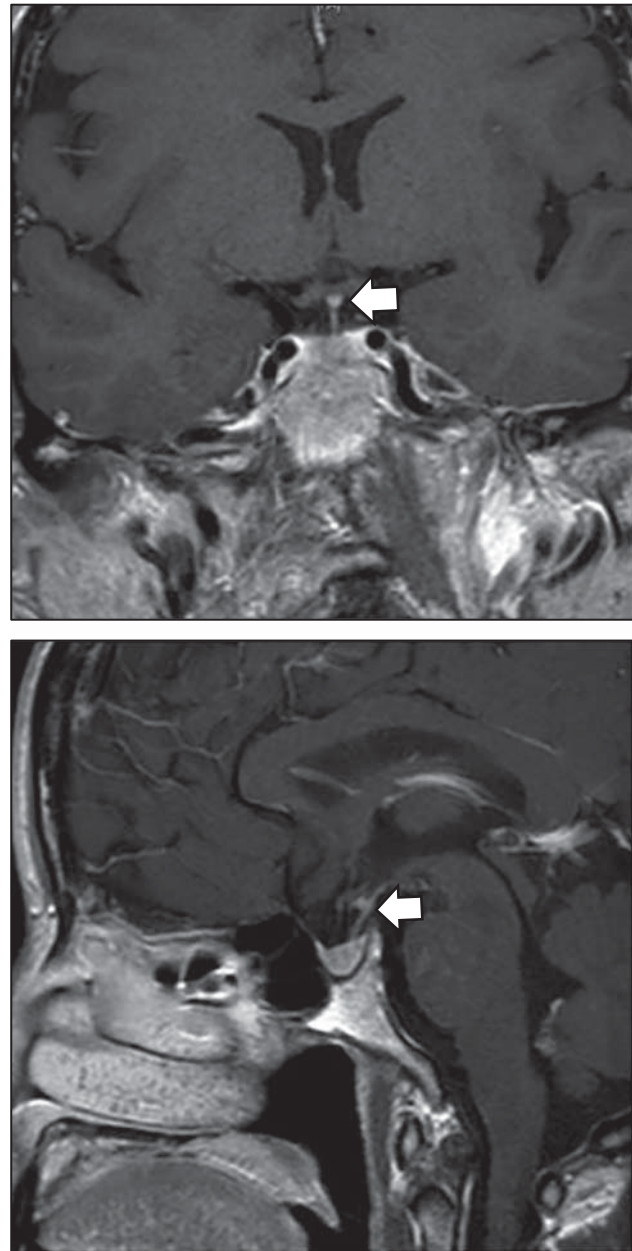
A 38-year-old Chinese woman was referred in the 37th week of her first single-gestation due to significant polyuria (around 7 l/day), nocturia (up to eight times a night) and polydipsia, worsening in the 6 weeks prior to presentation. She had been diagnosed with gestational diabetes mellitus in the second trimester, well controlled with diet alone. Her past medical history was unremarkable, she denied alcohol intake or smoking, and she was not taking any medication. Her father had type 2 diabetes mellitus, but there was no family history of endocrinopathy or liver disease. Physical examination demonstrated decreased skin turgor and her blood pressure was 102/63 mmHg, heart rate 78 beats/min and weight 53 kg (BMI 22.6 kg/m<sup>2</sup>).

## Investigation

Laboratory data were as follows: urine osmolality 89 mOsmol/kg (350–1000); serum osmolality 293 mOsmol/kg (278–295); serum sodium 144 mmol/l (135–145); potassium 4.1 mmol/l (3.5–5.0); urea 2.2 mmol/l (2.5–6.7), creatinine 34 µmol/l (54–145); serum morning cortisol 1044 nmol/l; thyroid-stimulating hormone 6.58 mU/l; free thyroxine 15.4 pmol/l (10.5–20.0 pmol/l); thyroid peroxidase antibodies <35 IU/ml; glucose 3.5 mmol/l and HbA1c 5.3%. Bilirubin, alanine transaminase, alkaline phosphatase, albumin, uric acid, creatinine and full blood count were within the normal reference range. The 24-h urine output prior to desmopressin was 7000 ml/24 h (overnight 2500 ml). Considering the risk of dehydration in pregnancy, a water deprivation test was not performed.

Twelve weeks after delivery, the pituitary magnetic resonance imaging (MRI) revealed that the

neurohypophyseal bright spot on the T1 image was situated ectopically, just anterior to the pituitary stalk. The anterior pituitary and the infundibulum were normal, excluding tumours or vascular abnormalities (Fig. 1). At this point, her sodium, serum and urine osmolality were also normal.



**Figure 1**  
Pituitary MRI performed 12-weeks *post-partum*. The neurohypophyseal T1-bright spot is situated ectopically (arrows). Tumours, pituitary mass, vascular malformations or findings compatible with lymphocytic infundibulo-neurohypophysitis were excluded.

## Treatment

The patient was started on oral desmopressin, 200 µg at night, with resolution of the nocturia. However, following diurnal persistence of polyuria and polydipsia, the dose was up-titrated to 200 µg twice daily, with improvement in all of her symptoms. On this therapeutic regimen, her serum and urine osmolality were 280 and 310 mOsm/kg respectively, and serum sodium was 138 mmol/l. The patient also treated with levothyroxine (25 µg/daily), following the thyroid function test results.

## Outcome and follow-up

A female fetus with a 1-min Apgar score of 10 was delivered at the 39th week, without complications. Eight weeks *post-partum* the patient stopped her desmopressin. At 12 weeks *post-partum*, her sodium, serum and urine osmolalities were within the normal reference range, and she no longer suffered from polyuria, polydipsia or nocturia. She remains clinically well, currently breast-feeding, with no problems.

## Discussion

Gestational DI is a rare complication of pregnancy occurring in two to four out of 100 000 pregnancies (1) (3). It usually develops in the end of second or third trimester of pregnancy and remits spontaneously 4–6 weeks after delivery (2) (3). Symptoms include hypotonic polyuria, polydipsia, fatigue, weight loss, decreased skin turgor and nausea, which usually develop over a few days, and which may worsen in the subsequent days/weeks if this condition is not properly identified and treated (4) (5).

Water balance is controlled by thirst and the secretion of arginine vasopressin (AVP), which in turn is primarily regulated by serum osmolality (6). In pregnancy, water metabolism is remarkably changed, with increased total body water, an expanded plasma volume (more than 1.5 times normal), and serum osmolality 'physiologically' decreases ~10 mOsm/kg compared to non-pregnant serum osmolality (7) (8). Thus, the osmolar threshold for AVP secretion changes to a lower level, which may be due to chorionic gonadotrophin resetting the fixed point of the osmostat in pregnancy (6) (7). Moreover, the thirst threshold also decreases in pregnancy (7). Hence, AVP secretion and thirst occur at a lower serum osmolality (3) (7) (8).

Gestational DI is thought to be mainly related to excessive vasopressinase activity, an enzyme expressed by

placental trophoblasts during pregnancy, which degrades AVP and therefore increases AVP clearance (2) (3) (7). The placental vasopressinase is a cysteine aminopeptidase with molecular weight of 330 kDa which inactivates AVP, oxytocin and other small peptides. Vasopressinase is produced from the 7th gestational week by the trophoblasts, increasing 1000-fold between the 7th and 40th weeks (coincident with the trophoblast mass rise), reaching maximal levels in the third trimester, and usually becomes undetectable 5–6 weeks after delivery (3) (4) (7). Its activity is proportional to the placenta weight, explaining the higher vasopressinase activity in the third trimester or in multiple pregnancy (3) (4) (8).

Vasopressinase is metabolised in the liver, explaining the higher concentrations of this enzyme in patients with hepatic dysfunction. Transient (acute fatty liver of pregnancy, HELLP syndrome and preeclampsia) or chronic (hepatitis, alcoholic hepatitis and cirrhosis) liver disease/damage decreases the hepatic degradation of vasopressinase, which in turn favours the metabolic AVP degradation (1) (7). Therefore, it is important to assess liver function in patients with gestational DI, but also to pay attention in pregnant women with liver dysfunction for the development of DI during pregnancy (1) (2) (7).

Other mechanisms may be involved in the establishment of gestational DI: i) increased blood circulation in liver and kidneys may contribute to enhanced AVP clearance; ii) resistance to the renal action of AVP due to the increased prostaglandin levels; iii) hypertrophy/hyperplasia of the adenohypophysis during pregnancy, which may compress the pituitary posterior lobe and iv) during pregnancy there is an increase in corticosteroids, progesterone and thyroxine concentrations, which may antagonise AVP (2). The degradation of AVP by vasopressinase may also unmask subclinical forms of DI, which may become symptomatic during pregnancy. Women who previously had neurosurgery or head trauma, or a familial history of DI, are in particular risk (5) (6).

In pregnancy, DI is initially identified by the presence of polyuria and polydipsia. This diagnosis is challenging, since water metabolism change during pregnancy; the water deprivation test is normally not recommended during pregnancy because it may lead to significant dehydration (1) (2) (5). Thus, the diagnosis is usually limited to assessment of urine and plasma osmolalities. The treatment of gestational DI requires 1-deamino-8-D-AVP (desmopressin), a synthetic form of AVP with a modified N-terminus and a second amino-acid change rendering it more resistant to vasopressinase (8) (9). Symptomatic improvement, and urine and plasma

osmolality normalisation with desmopressin is reassuring for the diagnosis (1) (3) (5) (8). Plasma sodium after the initiation of desmopressin treatment should be closely monitored to avoid hyponatraemia (9). The absence of previous individual/familial pituitary risk factors, the absence of liver dysfunction, the *post-partum* identification of the neurohypophyseal MRI bright T1-signal, the resolution of her symptoms and the normalisation of the laboratory tests after delivery, reinforce our diagnosis of transient gestational DI, most probably due to increased vasopressinase activity. The ectopic neurohypophysis, defined by the displacement of the posterior lobe, may be a normal variant and in this situation is not thought to be of pathological significance (6) (10).

This case illustrates some challenges in the diagnosis and management of the uncommon transient gestational DI. We highlight the need for clinical suspicion in pregnant women with typical DI symptoms, particularly in those with multiple pregnancies or liver dysfunction. The diagnostic challenges, which should rely on basal evaluations of serum and urine osmolality, rather than water deprivation test due to its risks in pregnancy. The treatment of this condition requires transient treatment with desmopressin.

---

**Declaration of interest**

The authors declare that there is no conflict of interest that could be perceived as prejudicing the impartiality of the research reported.

---

**Funding**

This research did not receive any specific grant from any funding agency in the public, commercial or not-for-profit sector.

---

**Patient consent**

Informed consent was obtained from the patient.

---

**Author contribution statement**

P Marques and A Grossman were involved in the care of this patient and in the production of the manuscript. K Gunawardana was involved in data collection and presentation.

---

**References**

- 1 Ananthakrishnan S 2009 Diabetes insipidus in pregnancy: etiology, evaluation, and management. *Endocrine Practice* **15** 377–382. (doi:10.4158/EP09090.RA)
- 2 Bellastella A, Bizzarro A, Colella C, Bellastella G, Sinisi A & De Bellis A 2012 Subclinical diabetes insipidus. *Best Practice & Research. Clinical Endocrinology & Metabolism* **26** 471–483. (doi:10.1016/j.beem.2011.11.008)
- 3 Wallia A, Bizhanova A, Huang W, Goldsmith S, Gossett D & Kopp P 2013 Acute diabetes insipidus mediated by vasopressinase after placental abruption. *Journal of Clinical Endocrinology and Metabolism* **98** 881–886. (doi:10.1210/jc.2012-3548)
- 4 Gambito R, Chan M, Sheta M, Ramirez-Arao P, Gurm H, Tunkel A & Nivera N 2012 Gestational diabetes insipidus associated with HELLP syndrome: a case report. *Case Reports in Nephrology* **2012** Article ID 640365. (doi:10.1155/2012/640365)
- 5 Kalelioglu I, Uzum AK, Yildirim A, Ozkan T, Gungor F & Has R 2007 Transient gestational diabetes insipidus diagnosed in successive pregnancies: review of pathophysiology, diagnosis, treatment, and management of delivery. *Pituitary* **10** 87–93. (doi:10.1007/s11102-007-0006-1)
- 6 Molitch ME 1998 Pituitary diseases in pregnancy. *Seminars in Perinatology* **22** 457–470. (doi:10.1016/S0146-0005(98)80026-8)
- 7 Schrier R 2010 Systemic arterial vasodilation, vasopressin, and vasopressinase in pregnancy. *Journal of the American Society of Nephrology* **21** 570–572. (doi:10.1681/ASN.2009060653)
- 8 Bueno JAS, Ortíz PV, Amat JH, Fernández VC, Manzano MC & Teruel RG 2005 Transient diabetes insipidus during pregnancy: a clinical case and a review of the syndrome. *European Journal of Obstetrics & Gynecology and Reproductive Biology* **118** 251–254. (doi:10.1016/j.ejogrb.2004.04.036)
- 9 Oiso Y, Robertson GL, Norgaard JP & Juul KV 2013 Treatment of neurohypophyseal diabetes insipidus. *Journal of Clinical Endocrinology and Metabolism* **98** 3958–3967. (doi:10.1210/jc.2013-2326)
- 10 Yamamoto T, Ishii T, Yoshioka K, Yamagami K, Yamakita T, Miyamoto M, Hosoi M, Sato T, Tanaka S & Fujii S 2003 Transient central diabetes insipidus in pregnancy with a peculiar change in signal intensity on T1-weighted magnetic resonance images. *Internal Medicine* **42** 513–516. (doi:10.2169/internalmedicine.42.513)

---

**Received in final form** 16 September 2015**Accepted** 23 September 2015