

Fluconazole in the treatment of Cushing's disease

Kharis Burns^{1,2}, Darshika Christie-David^{2,3} and Jenny E Gunton^{1,2,4,5,6}

¹Department of Diabetes and Endocrinology, Westmead Hospital, Sydney 2145, Australia

²Faculty of Medicine, Westmead Hospital, University of Sydney, Sydney 2145, Australia

³Department of Endocrinology, Royal North Shore Hospital, St Leonards 2065, Australia

⁴St Vincent's Clinical School, University of New South Wales, Sydney 2010, Australia

⁵Diabetes and Transcription Factors Group, Garvan Institute of Medical Research (GIMR), Sydney 2010, Australia

⁶Department of Diabetes, Obesity and Endocrinology, The Westmead Institute for Medical Research, The University of Sydney, Sydney 2145, Australia

Correspondence
should be addressed
to K Burns
Email
kbur9770@uni.sydney.edu.au

Summary

Ketoconazole was a first-line agent for suppressing steroidogenesis in Cushing's disease. It now has limited availability. Fluconazole, another azole antifungal, is an alternative, although its *in vivo* efficacy is unclear. A 61-year-old female presented with weight gain, abdominal striae and worsening depression. HbA1c increased to 76 mmol/mol despite increasing insulin. Investigations confirmed cortisol excess; afternoon serum cortisol was 552 nmol/l with an inappropriate ACTH of 9.3 pmol/l. In total, 24-h urinary free cortisol (UFC):creatinine ratio was 150 nmol/mmol with failure to suppress after 48 h of low-dose dexamethasone. Pituitary MRI revealed a 4-mm microadenoma. Inferior petrosal sinus sampling confirmed Cushing's disease. Transsphenoidal resection was performed and symptoms improved. However, disease recurred 6 months later with elevated 24-h UFC > 2200 nmol/day. Metyrapone was commenced at 750 mg tds. Ketoconazole was later added at 400 mg daily, with dose reduction in metyrapone. When ketoconazole became unavailable, fluconazole 200 mg daily was substituted. Urine cortisol:creatinine ratio rose, and the dose was increased to 400 mg daily with normalisation of urine hormone levels. Serum cortisol and urine cortisol:creatinine ratios remain normal on this regimen at 6 months. In conclusion, to our knowledge, this is the first case demonstrating prolonged *in vivo* efficacy of fluconazole in combination with low-dose metyrapone for the treatment of Cushing's disease. Fluconazole has a more favourable toxicity profile, and we suggest that it is a potential alternative for medical management of Cushing's disease.

Learning points:

- Surgery remains first line for the management of Cushing's disease with pharmacotherapy used where surgery is unsuccessful or there is persistence of cortisol excess.
- Ketoconazole has previously been used to treat cortisol excess through inhibition of CYP450 enzymes 11- β -hydroxylase and 17- α -hydroxylase, though its availability is limited in many countries.
- Fluconazole shares similar properties to ketoconazole, although it has less associated toxicity.
- Fluconazole represents a suitable alternative for the medical management of Cushing's disease and proved an effective addition to metyrapone in the management of this case.

Background

The management of pituitary adrenocorticotrophin (ACTH) Cushing's disease involves surgery as the first-line intervention. Medical therapy may be introduced to control cortisol excess in circumstances where disease is

not definitively cured via resection or there is a surgical contraindication (1) (2).

Ketoconazole was a first-line agent for suppressing adrenal steroid production in Cushing's disease, although it is now widely unavailable. Furthermore most medical



This work is licensed under a Creative Commons Attribution-NonCommercial-NoDerivs 3.0 Unported License.

© 2016 The authors

Downloaded from <http://www.edmcasereports.com>
via Open Access. This work is licensed under a Creative Commons Attribution-NonCommercial-NoDerivs 4.0 Unported License.
<http://creativecommons.org/licenses/by-nc-nd/4.0/>

therapies available to treat Cushing's Disease are associated with toxicity. Fluconazole, another azole antifungal, represents an alternative treatment option with a favourable adverse effect profile, although its *in vivo* efficacy has previously been unclear. This case demonstrates the novel and successful use of fluconazole in the management of Cushing's disease. Currently, with limited availability of ketoconazole and significant toxicities associated with other pharmacotherapies, fluconazole has been a suitable alternative.

Case presentation

A 61-year-old Indian female presented with weight gain, facial swelling, abdominal striae and worsening depression on a background of type 2 diabetes mellitus (T2DM), hypothyroidism, hypercholesterolemia, hypertension and ischemic heart disease. She had chronic shoulder pain, fibromyalgia and osteoporosis (lumbar spine T score -2.5) with no past fractures.

T2DM was managed with insulin aspart tds, insulin glargine nocte, metformin 1 g tds and gliclazide MR 120 mg. There was no history of corticosteroid use. Family history was significant for T2DM and ischaemic heart disease in her father. There was no family history of endocrine tumours. The patient was married with two children, was a non-smoker and drank no alcohol.

History additionally revealed 10 kg of weight gain over two years, blurred vision, easy bruising, fatigue and irritability. Her HbA1c deteriorated to 76 mmol/mol, from 66 mmol/mol, 18 months earlier, despite increasing insulin doses. Home blood glucose levels (BGL) revealed BGLs 306–407 mg/dl (17–22.6 mmol/l).

On examination, the patient had prominent supraclavicular and dorsocervical fat pads, moon facies, abdominal obesity and striae, proximal muscle weakness but no acanthosis nigricans. Her weight was 78.3 kg, height 157 cm and BMI 31.8 kg/m². Blood pressure was 148/85 mmHg and heart rate 80 bpm while on 4 anti-hypertensive medications. There was mild, long-standing pedal oedema.

Investigation

Initial investigations are shown in Table 1. An afternoon serum cortisol was 599 nmol/l. In total, 24-h urinary free cortisol (UFC) was 757 nmol/day. In all, 24-h UFC/creatinine ratio was elevated at 150.4 nmol/mmol (normal range 25–70). Cortisol failed to suppress during a 48-h low-dose dexamethasone suppression test (nadir 452 nmol/l, with ACTH 11.1 pmol/l). Similarly, no suppression was seen with high-dose dexamethasone. A pituitary MRI demonstrated a 4-mm left inferior microadenoma. Inferior petrosal sinus (IPS) sampling with corticotrophin-releasing

Table 1 Investigation results.

Test	Result	Reference range
24-h UFC	757 nmol/day	300–900 nmol/day
24-h UFC:creatinine ratio	150.4 nmol/mmol Cr	25–70 nmol/mmol Cr
Late afternoon cortisol	599 nmol/l	80–480 nmol/l
Afternoon cortisol	552 nmol/l	80–480 nmol/l
Paired afternoon ACTH	9.3 pmol/l	0–12 pmol/l
48-h 2-mg low-dose dexamethasone suppression test (0.5 mg q6h)		
Nadir cortisol	452 nmol/l	Expect cortisol suppressed <50 nmol/l at 48 h
48-h 8-mg high-dose dexamethasone suppression test (2 mg q6h)		
Nadir cortisol	450 nmol/l	
% Change from baseline	18.5% suppression	Expect >50% suppression for a positive test for Cushing's disease
CRH Stimulation		
Baseline ACTH	1.6 pmol/l	
Peak ACTH	12.6 pmol/l	Expect >50% increase in Cushing's disease
Baseline cortisol	197 nmol/l	
Peak cortisol	452 nmol/l	Expect >20% increase in Cushing's disease
IPS sampling		
Left IPS: peripheral ACTH ratio	12.3	Expect >2.0 in Cushing's disease
Right IPS: peripheral ACTH ratio	8.8	
Post-CRH left IPS: peripheral ACTH ratio	48.2	Expect >3.0 in Cushing's disease
Post-CRH right IPS: peripheral ACTH ratio	13.7	
Left IPS: peripheral prolactin ratio	1.9	Expect ≥ 1.8 in successful catheterisation
Right IPS: peripheral prolactin ratio	2.5	
Left: right prolactin-adjusted ACTH ratio	5.1	≥ 1.4 suggests lateralisation

hormone (CRH) stimulation confirmed a pituitary source of ACTH secretion and lateralised to the left with a ratio of 5.1 (>1.4 suggests lateralisation).

Transsphenoidal neurosurgery was performed. Histopathology showed only normal pituitary tissue. The patient was managed with hydrocortisone postoperatively with a weaning dose. Following withdrawal of hydrocortisone, the serum cortisol was 348 nmol/l, with ACTH 5.8 pmol/l. Over the next 2 months, she lost a small amount of weight, glycaemic control improved and her blood pressure normalised.

Approximately 6 months after the surgery, the patient again complained of weight gain, hypertension, hyperglycaemia and facial swelling. Home blood pressure recordings showed systolic readings >200 mmHg. Serum cortisol was 944 nmol/l with paired ACTH 22.0 pmol/l and repeat urine samples confirmed elevated cortisol:creatinine ratios.

Repeat MRI showed a 4-mm hypointense lesion in the floor of the pituitary fossa consistent with the original microadenoma.

Treatment

The patient was commenced on metyrapone 750 mg tds. She became clinically Addisonian with hypotension (BP 96/50 mmHg), postural dizziness, nausea and weight loss a few weeks after the commencement of therapy. A block and replace regimen was commenced, and hydrocortisone, at doses of 20 mg mane and 10 mg nocte, was added. The addition of hydrocortisone did not significantly affect the trend in biochemistry, although around 10 weeks after its commencement, the urine cortisol:creatinine ratio began to increase (Fig. 1). The hydrocortisone dose was later decreased to 15 mg mane and 8 mg nocte.

Definitive treatment options were discussed including repeat surgery, stereotactic radiotherapy and bilateral adrenalectomy. The patient declined repeat surgery and eventually opted for gamma-knife radiation treatment, though treatment was delayed for 6 months (Fig. 1).

Despite metyrapone, the urine cortisol levels remained elevated; spot urinary cortisol:creatinine ratio was 57.7 $\mu\text{mol/mol}$ (normal <30); so, ketoconazole 400 mg daily was added with good effect (Fig. 1). In all, 6 weeks later, the urine cortisol:creatinine ratio was normal 23.1 $\mu\text{mol/mol}$ (ref <30). Metyrapone was decreased to 500 mg bd, and the patient remained well-controlled for several months.

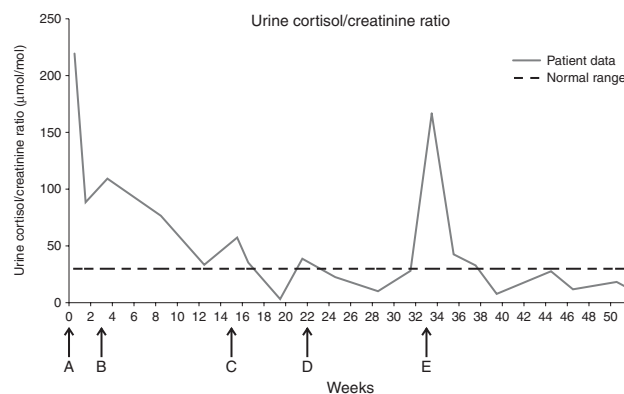


Figure 1

Trend of urine cortisol:creatinine ratio over time with the introduction of new therapies. A, metyrapone 750 mg tds commenced; B, hydrocortisone 20 mg mane/10 mg afternoon commenced 3 weeks later; C, ketoconazole 400 mg daily started, metyrapone reduced to 500 mg bd; D, fluconazole 200 mg daily started; E, fluconazole dose increased to 400 mg daily. Note: Radiotherapy commenced after the end of the period described above.

Then, ketoconazole became unavailable. After examination of the CYP450 activity of the various azoles, fluconazole was prescribed at 200 mg daily. This was increased to 400 mg daily, and her serum cortisol and urine cortisol:creatinine ratio normalised (Fig. 1).

Outcome and follow-up

In total, 6 months later, the patient remained stable on metyrapone and fluconazole, and her radiotherapy was administered. Following the commencement of radiotherapy, metyrapone was withdrawn and the patient remained stable on fluconazole alone at a dose of 400 mg daily. To our knowledge, this is the first case demonstrating prolonged *in vivo* efficacy of fluconazole as a steroid inhibitor for the treatment of Cushing's disease.

Discussion

First-line management of Cushing's disease is surgery. Medical therapy is used where disease is not cured via resection (1). Transsphenoidal pituitary tumour resection is quoted to be successful in up to 75–80% of cases with the remaining 20–25% requiring adjuvant pharmacotherapy (1). Recurrence occurs in ~20% of patients within 2–4 years (1).

Medical treatment options

In circumstances of persistent cortisol excess, or where surgery is contraindicated, pharmacotherapy may be

necessary (1) (3) (4). A range of medical therapies are available. Most drugs inhibit adrenal synthesis of cortisol. Ketoconazole, an imidazole derivative, has been used for its ability to block CYP450 enzymes 11- β -hydroxylase and 17- α -hydroxylase (1). At doses of 200–600 mg daily, it effectively inhibits adrenal and gonadal steroidogenesis. In cases of severe hypercortisolism, doses of up to 1200 mg daily may be used (5). Its ability to maintain a reduction in UFC and to rapidly improve and control the features of Cushing's syndrome has been well described and led to its recommendation as a first-line agent for medical management (4) (6).

Despite efficacy, ketoconazole is not without adverse effects. Hepatotoxicity is recognised, though usually mild to moderate, and the risk of severe hepatic failure is low (5). Gastrointestinal side effects are common, gynaecomastia is reported and, except in Cushing's syndrome, its CYP450 inhibition is undesirable (4) (5) (6).

Fluconazole is another azole compound and a recognised alternative to ketoconazole in the treatment of fungal infections. This drug has fewer side effects; in particular, hepatotoxicity is less common (7). Fluconazole is unique in chemical structure and pharmacologic profile (8). Historically, these two agents have been used for the treatment of similar conditions; however, there has been little investigation into the use of fluconazole as a treatment for Cushing's syndrome to date. One case report indicates benefit in cortisol excess due to adrenal carcinoma (3), and its efficacy in ectopic ACTH production has also recently been recognised (9). There are no reports of its use in Cushing's disease. In contrast, several case reports discount any ability of this medication to suppress cortisol production (10) (11).

Nevertheless, case reports document incidental adrenal suppression as a side effect of fluconazole used for antifungal purposes. Further reports have documented adrenal insufficiency as a result of inhibition of fluconazole metabolism through interactions with medications utilising the same CYP450 pathway (12). This 'adverse effect' demonstrates its ability to inhibit steroidogenesis and suggests potential benefit in Cushing's syndrome.

In vitro studies have proven the ability of fluconazole to suppress human cortisol production in cultured adrenal cortical carcinoma and human adrenal cortical cells (13). Specifically, the ability of fluconazole to block the activity of 11- β -hydroxylase and 17- α -hydroxylase enzymes has been confirmed (13). One study comparing the *in vitro* potency of ketoconazole and fluconazole found higher potency with the former, though confirmed a reduction in cortisol with fluconazole use (13).

Fluconazole and CYP450 interaction

The ability of ketoconazole to suppress steroidogenesis has been attributed to binding and subsequent impairment of CYP450 enzyme action. Pharmacokinetic studies have shown that fluconazole similarly inhibits CYP450 enzymes; however, ketoconazole is at least three-fold more potent (14). Ketoconazole is extensively hepatically metabolised, potentially contributing to increased hepatotoxicity (8). In contrast, fluconazole is minimally metabolised, with 80% excreted unchanged in the urine (8).

This case shows that fluconazole may be a suitable alternative to ketoconazole in the medical management of Cushing's disease. Despite conflicting reports in the literature, we report successful suppression of urine cortisol:creatinine ratio in a patient with Cushing's disease, over 6 months of treatment with fluconazole. While it is recognised that variability in urine cortisol excretion exists in patients with Cushing's disease, the rise in cortisol following ketoconazole cessation and subsequent biochemical improvement with the introduction of fluconazole supports efficacy of fluconazole in controlling cortisol excess. Given a more favourable toxicity profile and issues with ketoconazole access, we suggest that fluconazole is a possible alternative in the medical management of Cushing's disease where surgery is unsuccessful, declined by the patient or contraindicated.

Declaration of interest

The authors declare that there is no conflict of interest that could be perceived as prejudicing the impartiality of the research reported.

Funding

This research did not receive any specific grant from any funding agency in the public, commercial or not-for-profit sector.

Patient consent

Written informed consent has been obtained from the patient, and a signed copy of the consent form is provided.

Author contribution statement

All three authors, Dr K Burns, Dr D Christie-David and Professor J E Gunton contributed to the preparation of this manuscript.

References

- 1 Schteingart DE 2009 Drugs in the medical treatment of Cushing's syndrome. *Expert Opinion on Emerging Drugs* **14** 661–671. (doi:10.1517/14728210903413522)

- 2 Castinetti F, Morange I, Jaquet J, Conte-Devolx B & Brue T 2008 Ketoconazole revisited: a preoperative or postoperative treatment in Cushing's disease. *European Journal of Endocrinology/European Federation of Endocrine Societies* **158** 91–99. (doi:10.1530/EJE-07-0514)
- 3 Riedl M, Maier C, Zettinig G, Nowotny P, Schima W & Luger A 2006 Long term control of hypercortisolism with fluconazole: case report and *in vitro* studies. *European Journal of Endocrinology/European Federation of Endocrine Societies* **154** 519–524. (doi:10.1530/eje.1.02120)
- 4 Nieman LK 2002 Medical therapy of Cushing's disease. *Pituitary* **5** 77–82. (doi:10.1023/A:1022308429992)
- 5 Castinetti F, Guignat L, Giraud P, Muller M, Kamenicky P, Drui D, Caron P, Luca F, Donadille B, Vantyghem MC *et al.* 2014 Ketoconazole in Cushing's disease: is it worth a try? *Journal of Clinical Endocrinology and Metabolism* **99** 1623–1630. (doi:10.1210/jc.2013-3628)
- 6 Sonino N, Boscaro M, Paoletta A, Mantero F & Ziliotto D 1991 Ketoconazole treatment in Cushing's syndrome: experience in 34 patients. *Clinical Endocrinology* **35** 347–352. (doi:10.1111/j.1365-2265.1991.tb03547.x)
- 7 Garcia Rodriguez LA, Duque A, Castellsague J, Perez-Gutthann S & Stricker BH 1999 A cohort study on the risk of acute liver injury among users of ketoconazole and other antifungal drugs. *British Journal of Clinical Pharmacology* **48** 847–852. (doi:10.1046/j.1365-2125.1999.00095.x)
- 8 Como JA & Dismukes WE 1994 Oral azole drugs as systemic antifungal therapy. *New England Journal of Medicine* **330** 263–272. (doi:10.1056/NEJM199401273300407)
- 9 Schwetz V, Aberer F, Stiegler C, Pieber TR, Obermayer-Pietsch B & Pilz S 2015 Fluconazole and acetazolamide in the treatment of ectopic Cushing's syndrome with severe metabolic alkalosis. *Endocrinology, Diabetes & Metabolism Case Reports* **2015** Article ID: 150027. (doi:10.1530/EDM-15-0027)
- 10 Magill SS, Puthanakit T, Swoboda SM, Carson KA, Salvatori R, Lipsett PA & Hendrix CW 2004 Impact of fluconazole prophylaxis on cortisol levels in critically ill surgical patients. *Antimicrobial Agents and Chemotherapy* **48** 2471–2476. (doi:10.1128/AAC.48.7.2471-2476.2004)
- 11 Michaelis G, Zeiler D, Biscopring J, Fussle R & Hempelmann G 1993 Function of the adrenal cortex during therapy with fluconazole in intensive care patients. *Mycoses* **36** 117–123. (doi:10.1111/j.1439-0507.1993.tb00698.x)
- 12 Johnson SR, Marion AA, Vrchtickey T, Emmanuel P & Lujan-Zilbermann J 2006 Cushing syndrome with secondary adrebal insufficiency from concomitant therapy with ritonavir and fluticasone. *Journal of Pediatrics* **148** 386–388. (doi:10.1016/j.jpeds.2005.11.034)
- 13 van der Pas R, Hofland LJ, Hofland J, Taylor AE, Arlt W, Steenbergen J, van Koetsveld PM, de Herder WW, de Jong FH & Feelders RA 2012 Fluconazole inhibits human adrenocortical steroidogenesis *in vitro*. *Journal of Endocrinology* **215** 403–412. (doi:10.1530/JOE-12-0310)
- 14 Ervine C, Matthew D, Brennan B & Houston J 1996 Comparison of ketoconazole and fluconazole as cytochrome P450 inhibitors. Use of steady-state infusion approach to achieve plasma concentration–response relationships. *Drug Metabolism and Disposition: the Biological Fate of Chemicals* **24** 211–215.

Received in final form 14 January 2016

Accepted 20 January 2016