

A novel *TRPM6* variant (c.3179T>A) causing familial hypomagnesemia with secondary hypocalcemia

Sara Lomelino-Pinheiro¹, Margarida Bastos² and Adriana de Sousa Lages²

¹Endocrinology Department, Instituto Português de Oncologia de Lisboa Francisco Gentil, Lisboa, Portugal and

²Endocrinology, Diabetes and Metabolism Department, Centro Hospitalar Universitário de Coimbra, Coimbra, Portugal

Correspondence
should be addressed
to S Lomelino-Pinheiro

Email
saralomelinopinheiro@gmail.com

Summary

Familial hypomagnesemia with secondary hypocalcemia (FHS) is a rare autosomal recessive disorder (OMIM# 602014) characterized by profound hypomagnesemia associated with hypocalcemia. It is caused by mutations in the gene encoding transient receptor potential cation channel member 6 (TRPM6). It usually presents with neurological symptoms in the first months of life. We report a case of a neonate presenting with recurrent seizures and severe hypomagnesemia. The genetic testing revealed a novel variant in the *TRPM6* gene. The patient has been treated with high-dose magnesium supplementation, remaining asymptomatic and without neurological sequelae until adulthood. Early diagnosis and treatment are important to prevent irreversible neurological damage.

Learning points:

- Loss-of-function mutations of *TRPM6* are associated with FHS.
- FHS should be considered in any child with refractory hypocalcemic seizures, especially in cases with serum magnesium levels as low as 0.2 mM.
- Normocalcemia and relief of clinical symptoms can be assured by administration of high doses of magnesium.
- Untreated, the disorder may be fatal or may result in irreversible neurological damage.

Background

Familial hypomagnesemia with secondary hypocalcemia (FHS) is a rare autosomal recessive disorder (OMIM# 602014) caused by mutations in the gene encoding TRPM6 (transient receptor potential melastatin 6) on chromosome 9q22 (1). This channel is responsible for epithelial absorption of magnesium in the colon and renal distal convoluted tube (DCT) (2). The primary defect is impaired intestinal absorption of magnesium with secondary renal excretion (1, 3). FHS is considered a rare medical condition, although its prevalence is unknown with fewer than a hundred cases reported in the literature. No racial or familial association have been described, but parental consanguinity is often present (4, 5).

The disorder is characterized by severe hypomagnesemia and secondary hypocalcemia (4, 6). A measured serum magnesium concentration as low as 0.2 mmol/L, or even lower, is not uncommon in these patients (5, 7). FHS typically presents in the neonatal period with symptoms and signs of neuromuscular hyperexcitability (hyperactivity, tetany) and seizures, refractory to antiepileptic therapy (1, 5). Prolonged untreated hypomagnesemia may lead to developmental delay, intellectual disability, failure to thrive and severe cardiomyopathy (4, 8). Genetic testing allows the identification of mutations in the *TRPM6* gene, encoding the epithelial magnesium channel TRPM6 causing FHS.



Acute treatment consists of i.v. magnesium administration leading to relief of clinical symptoms and normocalcemia, followed by lifelong oral magnesium supplementation (4). Early diagnosis and treatment are essential to prevent death and long-term neurodevelopmental sequelae (4, 9). We report the presentation and follow-up of a boy with a novel *TRPM6* variant.

Case presentation

A 27-day-old male neonate, firstborn to nonconsanguineous parents, was admitted in the Emergency Department due to generalized tonic-clonic seizures lasting less than 3 min and irritability for the past 12 h. He was born full-term, via vaginal delivery, with the use of forceps with adequate somatometry parameters at birth (Table 1). There was no history of neonatal hypoxia or other adverse perinatal events. He was exclusively breastfed for the first 26 days postpartum. The family history was unremarkable. There was no associated fever or any other signs of infection in the preceding days. General and neurologic examinations were normal. There was no developmental delay or dysmorphic features.

Despite treatment with i.v. phenobarbital at a dose of 10 mg/kg/day, the seizures were not controlled, so the patient was transferred to the Pediatric Intensive Care Unit for detailed etiologic investigation.

Investigation

A basic workup revealed severe hypocalcemia 1.30 mmol/L (NR: 2.10–2.55), hyperphosphatemia 2.58 mmol/L (NR: 1.25–2.10) and hypomagnesemia 0.48 mmol/L (NR: 0.70–1.00). An inadequate parathormone serum level of 16 pg/mL (NR: 15–35) was found. Fractional excretion of magnesium (FE Mg) was <1.4% (NR: 2–4%) in the face of severe hypomagnesemia and tubular phosphorus reabsorption rate was 99%. The remaining serum ions and arterial blood gases were within normal range. Renal and liver function tests were normal. Transfontanellar and cardiac ultrasound were normal, as well as the EKG data.

Table 1 Somatometric characteristics at birth.

Characteristics	Value	Percentile
Weight	3050 g	50
Length	48 cm	50
Head circumference	34 cm	50

Lumbar puncture showed no remarkable changes. Initial investigation workup is showed in Table 2.

Treatment

The following diagnoses were initially considered: neonatal late-onset hypocalcemia and primary hypoparathyroidism. However, despite treatment with high doses of i.v. calcium gluconate (100 mg/kg/day), calcium levels did not substantially increase and the child experienced recurrent seizures and episodes of atrial tachycardia. In view of severe hypomagnesemia, the possibility of FHS was considered and treatment with high doses of i.v. magnesium was promptly initiated. Three days later, there was relief from clinical symptoms as well as rapid biochemical response. The infusion of calcium gluconate was gradually discontinued in parallel with an increase in the dose of magnesium sulfate (0.7 mmol/kg/day), with normalization of calcemia. The patient remained clinically asymptomatic and was discharged 18 days later on oral magnesium therapy (0.35 mmol/kg/day).

Outcome and follow-up

The patient had regular appointments at a local Pediatric Hospital and had been clinically stable with serum magnesium values between 0.64 and 1.02 mmol/L (NR: 0.70–1.00 mmol/L). However, at the age of 8 months, he was readmitted with seizures, related to poor compliance with magnesium oral supplementation during the past 7 days. The child presented with a serum magnesium of 0.20 mmol/L (NR: 0.70–1.00) and a low serum calcium of 1.75 mmol/L (NR: 2.10–2.55). Full clinical and biochemical recovery was noted after isolated treatment with high doses of i.v. magnesium (0.7 mmol/kg/day) and the patient was discharged 6 days later. During replacement therapy, there was an increase in fractional excretion of magnesium (FE of Mg) to 4.7%.

The boy maintained regular follow-up in endocrinology appointments, showing good motor and cognitive development. He remained seizure-free on oral magnesium supplements until 19 years old. At this age, he was admitted once more with seizures and hypomagnesemia of 0.22 mmol/L, with a favorable response to an increase in magnesium daily dose.

Nowadays, the patient is 27 years old and is clinically stable with no neurologic sequelae, having completed his university science education. He sometimes refers muscle cramps. He is currently medicated with magnesium



Table 2 Initial investigation workup.

Investigation	Result	Normal range
Calcium (mmol/L)	1.30	2.10–2.55
Phosphorus (mmol/L)	2.58	1.25–2.10
Magnesium (mmol/L)	0.48	0.70–1.00
Sodium (mmol/L)	137	135–145
Potassium (mmol/L)	4.0	3.5–4.5
Parathormone (pg/mL)	16	15–35
Fractional excretion of magnesium (%)	<1.4	2.0–4.0
Tubular phosphorus reabsorption rate (%)	99	
Electrocardiogram	No signs of hypocalcemia	
Cardiac ultrasound	No changes	
Transfontanellar ultrasound	No changes	
Lumbar puncture	No signs of infection	

aspartate 7377.6 mg/day and attending endocrinology appointments biannually. Flatulence and abdominal discomfort are reported as an occasional side-effect of the medication. Clinical and laboratorial findings together pointed to a diagnosis of FSHH in early infancy and genetic diagnostic confirmation was possible at 25 years.

A next-generation sequencing (NGS) panel for the study of hypomagnesemia including 17 genes (*BSND*, *CASR*, *CLCNKB*, *CLDN16*, *CLDN19*, *CNNM2*, *EGF*, *EGFR*, *FAM111A*, *FXYD2*, *HNF1B*, *KCNA1*, *KCNJ10*, *PCBD1*, *SARS2*, *SLC12A3* and *TRPM6*) revealed an homozygous variant c.3179T>A (p.Ile1060Asn) in the *TRPM6* gene, representing a likely pathogenic variant. The DNA sequence chromatograms are displayed in Fig. 1. Parental and half-brother plasma magnesium concentrations are within the normal range and there is no family history of similar neurological findings or neonatal deaths due to unknown cause. This is a unique case in the family. Familial genetic analysis was not yet performed.

Discussion

Mutations in the *TRPM6* gene, encoding the epithelial magnesium channel TRPM6, have been proven to be the molecular cause of hypomagnesemia with secondary hypocalcemia. We present a case of FSHH with a novel *TRPM6* gene variant c.3179T>A (p.Ile1060Asn). As far as we know, this homozygous variant c.3179T>A has not yet been described in the medical literature and has not been identified in population databases (dbSNP or gnomAD). The variant was considered likely pathogenic according to the Standards and Guidelines for the Interpretation of Sequence Variants: A Joint Consensus Recommendation of the American College of Medical Genetics and Genomics and the Association for Molecular Pathology. The *in silico* analysis (SIFT, polyphen and mutation taster) showed that

it is located in a functional domain of the protein without benign variation. Furthermore, it is absent (or present at extremely low frequency) from controls in Exome Sequencing Project, 1000 Genomes or ExAC. Multiple lines of computational evidence support a deleterious effect on the gene, with nine pathogenic predictions from DANN, DEOGEN2, EIGEN, FATHMM-MKL, M-CAP, MutationAssessor, MutationTaster, PrimateAI and SIFT vs two benign predictions from MVP and REVEL. Within this line, the authors considered the variant found in the patient to be likely pathogenic, especially associated with the clinical manifestations at presentation. This case offers important extended insight into the long-term follow-up of FSHH.

FSHH is a rare autosomal recessive disorder caused by loss-of-function mutations in the *TRPM6* gene. This gene encodes a magnesium permeable channel expressed in the distal segment of the intestine and the distal convoluted renal tubule (1, 10). Pathophysiology is related to impaired intestinal absorption of magnesium accompanied by renal magnesium wasting as a result of a reabsorption defect in the distal convoluted tubule (1, 7). Affected individuals have normal or low fractional magnesium excretions at diagnosis, in the face of severe hypomagnesemia. The renal magnesium leak with increase in FE of Mg excretion only becomes apparent once the serum magnesium concentration rises after adequate replacement (4, 7). In this sense, the diagnose is sometimes delayed, by the fact that renal magnesium wasting is not detectable during phases of profound hypomagnesemia (5). The serum magnesium levels of hypomagnesemic patients should be increased by means of i.v. magnesium supplementation before the FE of Mg is measured (2, 7).

FSHH is characterized by severe hypomagnesemia associated with hypocalcemia (1). Hypomagnesemia does not lead to significant signs and symptoms until

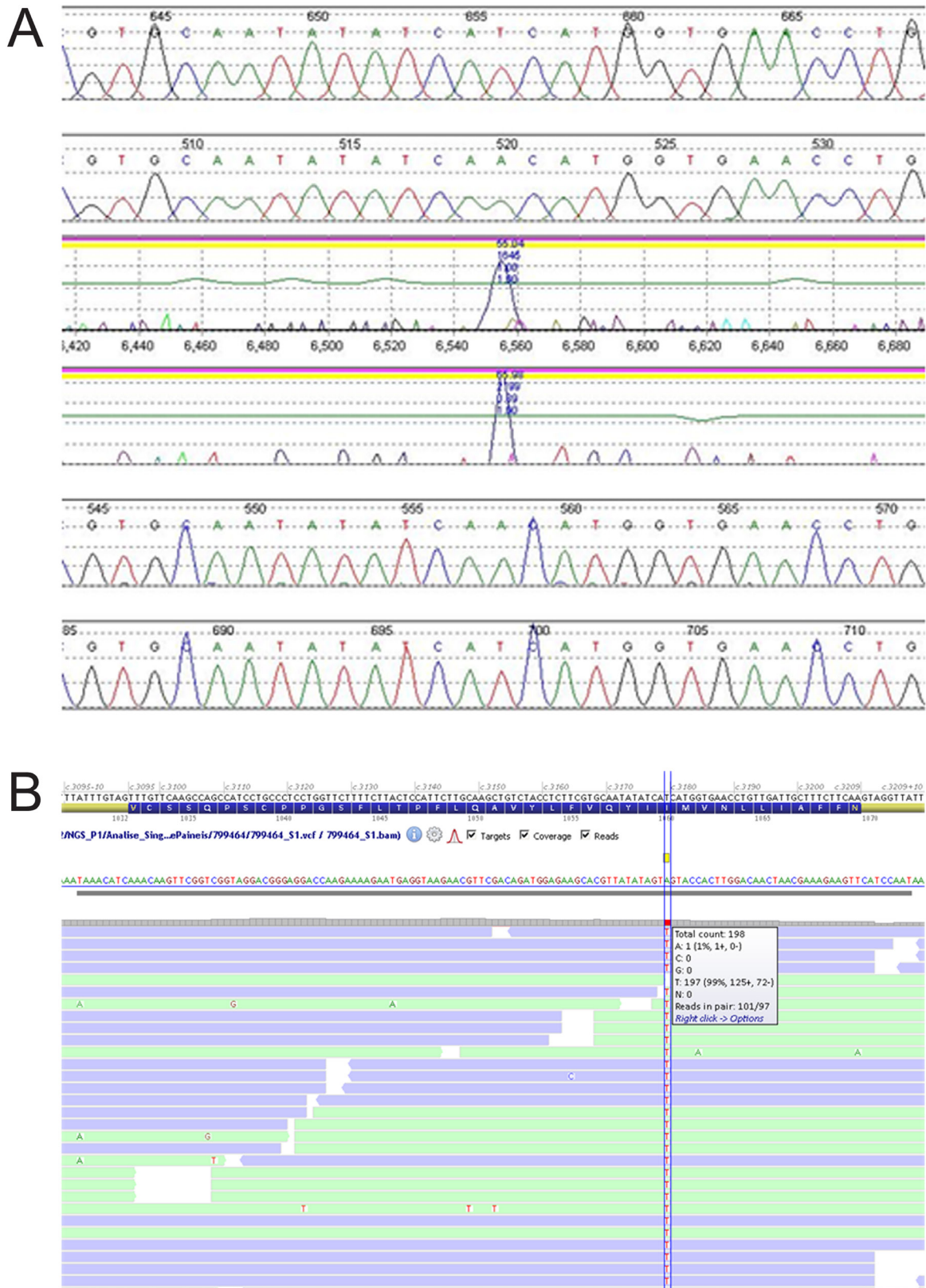


Figure 1
DNA sequence chromatograms (courtesy of CGC Genetics laboratory).



serum levels fall below 0.5 mmol/L (10). Clinical manifestations involve neuromuscular hyperexcitability, including tremors, tetany, convulsions and coma (7). Atrial and ventricular arrhythmias may arise not solely for the hypomagnesemia, but also from the associated hypocalcemia (10). Hypoparathyroidism is thought to result from an inhibition of PTH synthesis and secretion induced by extreme hypomagnesemia, leading to secondary hypocalcemia (4, 7).

Treatment usually consists of acute i.v. magnesium supplementation leading to relief of clinical symptoms and normocalcemia, followed by lifelong oral magnesium supplementation (1, 4). The observation that individuals with FSHH achieve (sub)normal serum magnesium levels by high oral magnesium intake, although they show impaired intestinal magnesium absorption, supports the theory of two independent pathways of magnesium transport in the intestine: an active transcellular system, which is defective in FSHH (TRPM6 represents a molecular component of the active transcellular pathway), and a passive paracellular pathway, which increases with rising intraluminal magnesium concentrations (1, 10). High oral magnesium doses are sufficient to overcome the phenotype of mutant TRPM6 by increasing paracellular magnesium absorption (1).

After correction of hypomagnesemia, serum levels should be monitored closely to prevent recurrence of symptoms (8). They usually remain in the subnormal range despite adequate therapy, probably due to the renal magnesium leak, which prevents an adequate conservation of the absorbed magnesium under supplementation (4). This may explain the occasional symptoms of muscular spasms reported by our patient.

Although it is a rare disease, FSHH should be considered in any pediatric patient presenting with refractory hypocalcemic seizures and severe hypomagnesemia. If it is early diagnosed and properly treated, patients may present normal physical and neurological development with good health outcomes in adulthood.

Diagnosis is confirmed by typical signs and symptoms of hypomagnesemia during early infancy and can be further solidified with genetic sequencing of the *TRPM6* gene.

Patient's perspective

For me, as a child, it was very hard to accept my difference, this continuing need to take medication, doing blood analysis and going to the hospital frequently. Now as an adult, the four major problems of living with this disease are: (1.) the high costs associated with magnesium supplements; (2.) the bad days of constant muscle cramps, especially in the lower limbs; (3.) flatulence and abdominal pain as a side-effect of the medication and

(4.) the fear of transmitting my condition to a child, knowing all the very hard moments that my parents and I went through.

Declaration of interest

The authors declare that there is no conflict of interest that could be perceived as prejudicing the impartiality of this case report.

Funding

This research did not receive any specific grant from any funding agency in the public, commercial or not-for-profit sector.

Patient consent

Written informed consent has been obtained from the patient for publication of the submitted article.

Author contribution statement

S L P and A S L wrote the case report. M B was responsible for the case management. All the authors read and approved the final manuscript.

Acknowledgements

The authors acknowledge Prof Branca Cavaco, Dr Ana Saramago, Dr Carolina Pires and Dr Tiago Silva for the important contribution regarding the genetic analysis.

References

- 1 Schlingmann KP, Weber S, Peters M, Nejsum LN, Vitzthum H, Klingel K, Kratz M, Haddad E, Ristoff E, Dinour D, *et al.* Hypomagnesemia with secondary hypocalcemia is caused by mutations in TRPM6, a new member of the TRPM gene family. *Nature Genetics* 2002 **31** 166–170. (<https://doi.org/10.1038/ng889>)
- 2 San-Cristobal P, Dimke H, Hoenderop JG & Bindels RJ. Novel molecular pathways in renal magnesium transport: a guided tour along the nephron. *Current Opinion in Nephrology and Hypertension* 2010 **19** 456–462. (<https://doi.org/10.1097/MNH.0b013e32833caf61>)
- 3 Wlader RY, Landau D, Meyer P, Shalev H, Tsolia M, Borochowitz Z, Boettger MB, Beck GE, Englehardt RK, Carmi R, *et al.* Mutation of TRPM6 causes familial hypomagnesemia with secondary hypocalcemia. *Nature Genetics* 2002 **31** 171–174. (<https://doi.org/10.1038/ng901>)
- 4 Schlingmann KP, Sassen MC, Weber S, Pechmann U, Kusch K, Pelken L, Lotan D, Syrrou M, Prebble JJ, Cole DEC, *et al.* Novel TRPM6 mutations in 21 families with primary hypomagnesemia and secondary hypocalcemia. *Journal of the American Society of Nephrology* 2005 **16** 3061–3069. (<https://doi.org/10.1681/ASN.2004110989>)
- 5 Lainez S, Schlingmann KP, van der Wijst J, Dworniczak B, van Zeeland F, Konrad M, Bindels RJ & Hoenderop JG. New TRPM6 missense mutations linked to hypomagnesemia with secondary hypocalcemia. *European Journal of Human Genetics* 2014 **22** 456–462. (<https://doi.org/10.1038/ejhg.2013.178>)
- 6 Paunier L, Radde IC, Kooh SW, Conen PE & Fraser D. Primary hypomagnesemia with secondary hypocalcemia in an infant. *Pediatrics* 1968 **41** 385–402.



- 7 Viering DHM, de Baaij JHF, Walsh SB, Kleta R & Bockenhauer D. Genetic causes of hypomagnesemia, a clinical overview. *Pediatric Nephrology* 2017 **32** 1123–1135. (<https://doi.org/10.1007/s00467-016-3416-3>)
- 8 Patel S, Rayanagoudar G & Gelding S. Case report: Familial hypomagnesaemia with secondary hypocalcaemia. *British Medical Journal Case Reports* 2016 **2016** bcr2016216870. (<https://doi.org/10.1136/bcr-2016-216870>)
- 9 Kamate M, Singh N & Patil S. Familial hypomagnesemia with secondary hypocalcemia mimicking neurodegenerative disorder. *Indian Pediatrics* 2015 **52** 521–522. (<https://doi.org/10.1007/s13312-015-0668-0>)
- 10 Pham PC, Pham PA, Pham S, Pham PT & Pham PM. Hypomagnesemia: a clinical perspective. *International Journal of Nephrology and Renovascular Disease* 2014 **7** 219–230. (<https://doi.org/10.2147/IJNRD.S42054>)

Received in final form 27 February 2020

Accepted 6 April 2020

6