



# Epidermoid cyst abscess of the neck masquerading as a thyroid abscess

Waralee Chatchomchaun<sup>1</sup>, Yotsapon Thewjitcharoen<sup>1</sup>, Karndumri Krittadhee<sup>1</sup>, Veekij Veerasomboonsin<sup>1</sup>, Soontaree Nakasatien<sup>1</sup>, Sirinate Krittiyawong<sup>1</sup>, Sriurai Porramatikul<sup>1</sup>, Ekgaluck Wanathayanoroj<sup>1</sup>, Auchi Kanchanapituk<sup>1</sup>, Pairoj Junyangdikul<sup>2</sup> and Thep Himathongkam<sup>1</sup>

<sup>1</sup>Diabetes and Thyroid Center, Theptarin Hospital, Bangkok, Thailand and <sup>2</sup>Department of Pathology, Samitivej Srinakarin Hospital, Bangkok Hospital Group, Bangkok, Thailand

Correspondence  
should be addressed  
to W Chatchomchaun  
**Email**  
[waralee.md@gmail.com](mailto:waralee.md@gmail.com)

## Summary

In this case report, we describe a 37-year-old male who presented with fever and tender neck mass. Neck ultrasonography revealed a mixed echogenic multiloculated solid-cystic lesion containing turbid fluid and occupying the right thyroid region. Thyroid function tests showed subclinical hyperthyroidism. The patient was initially diagnosed with thyroid abscess and he was subsequently treated with percutaneous aspiration and i.v. antibiotics; however, his clinical symptoms did not improve. Surgical treatment was then performed and a pathological examination revealed a ruptured epidermoid cyst with abscess formation. No thyroid tissue was identified in the specimen. The patient was discharged uneventfully. However, at the 3-month and 1-year follow-ups, the patient was discovered to have developed subclinical hypothyroidism. Neck ultrasonography revealed a normal thyroid gland. This report demonstrates a rare case of epidermoid cyst abscess in the cervical region, of which initial imaging and abnormal thyroid function tests led to the erroneous diagnosis of thyroid abscess.

## Learning points:

- Epidermoid cyst abscess at the cervical region can mimic thyroid abscess.
- Neck ultrasonography cannot distinguish thyroid abscess from epidermoid cyst abscess.
- Thyroid function may be altered due to the adjacent soft tissue inflammation.

## Background

Neck mass is a common problem in clinical practice. In general, the diagnostic approach is based on the immune status of the patient, the location of the lesion, and the duration and onset of symptoms. Neck masses around the thyroid region can involve the thyroid gland itself or the adjacent surrounding tissue (1). Thyroglossal duct cysts, brachial cleft cysts, skin inclusion cysts, and lymph nodes are the major differential diagnoses and can be confused with thyroid masses. Epidermoid cyst (EC) is a type of benign skin inclusion cyst that can be found in every part of the body from the scalp, face, neck, trunk,

and lower extremities (2). However, it is extremely rare in the thyroid region. Typically, ECs are asymptomatic, but superimposed infection, rupture, or malignant transformation can occur (2). Herein, we present the case of an EC abscess of the neck mimicking a thyroid abscess in a 37-year-old man.

## Case presentation

A 37-year-old male presented to our endocrine clinic with a 6-week history of a tender, palpable neck mass.

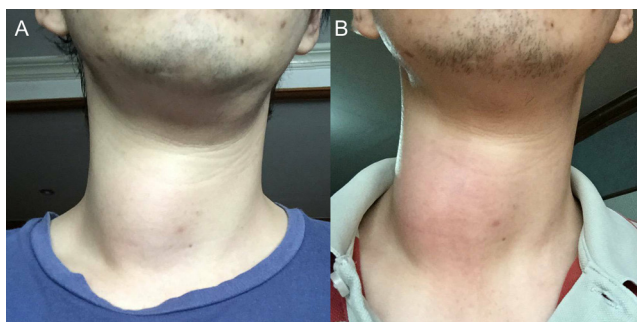

He denied any underlying pre-existing thyroid disease or neck trauma. Two months before this visit, he had been diagnosed with Varicella infection and was treated with oral acyclovir. Two weeks prior to this visit, he experienced sore throat and progressive swelling of the neck without signs of skin inflammation (Fig. 1A). In addition, he reported palpitations and mild tremor. His thyroid function tests showed an increase in free thyroxine (T4) level and free tri-iodothyronine (T3) level and a diagnosis of thyroiditis was made. Oral prednisolone and naproxen were given for a week. However, due to the worsening of his symptoms, including an expanding neck mass and new fever, he was referred to our clinic.

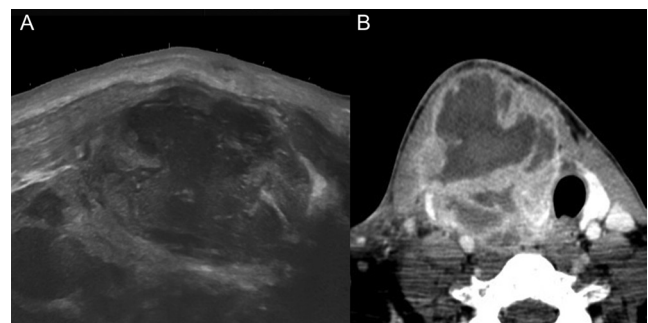
### Investigation and treatment

Upon a physical examination, the patient was considered normal but with mild anxiety. His vital signs included a body temperature of 38.5°C, heart rate of 99 b.p.m, blood pressure of 124/74 mmHg, and respiratory rate of 18 breaths per minute. An examination of the neck showed an anterior neck mass with tenderness and tense consistency (Fig. 1B). No dental caries or other signs of skin infection at the neck region were present. His laboratory investigations revealed a leukocytosis level of  $15\ 010 \times 10^6/L$  (normal range:  $4000\text{--}11\ 000 \times 10^6/L$ ). His thyroid function tests revealed subclinical hyperthyroidism, with a very low thyroid-stimulating hormone (TSH) level of 0.008  $\mu\text{IU/mL}$  (normal range: 0.3–4.1  $\mu\text{IU/mL}$ ). His serum free T4 and free T3 levels were normal at 1.33  $\mu\text{g/dL}$  (normal range: 0.8–1.8  $\mu\text{g/dL}$ ) and 1.9  $\text{ng/dL}$  (normal range: 1.6–4.0  $\text{ng/dL}$ ), respectively. Anti-thyroid peroxidase antibodies and thyroglobulin antibodies were negative. Neck ultrasonography revealed a mixed echogenic multiloculated solid-cystic lesion containing turbid fluid and occupying the right thyroid

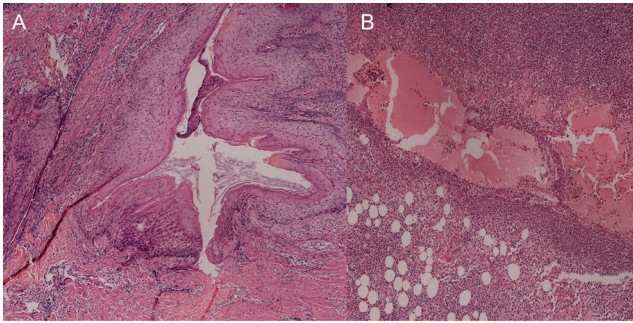
region with surrounding inflammatory changes (Fig. 2A). A color Doppler ultrasonography revealed a slightly decreased vascularity. The patient was given a diagnosis of thyroid abscess and was admitted for i.v. antibiotics. Percutaneous needle aspiration was performed and yielded about 9 mL of foul-smelling pus. Gram-staining of the pus showed mixed organisms with gram-positive cocci and gram-negative bacilli. Empirical antibiotic treatment with i.v. amoxycillin/clavulanic acid was initiated. Despite antibiotic treatment for 3 days, the neck mass showed progressive enlargement and the patient had persistent fever. He started to have hoarseness of his voice and difficulty swallowing. Re-aspiration was performed and 2 mL of dense pus was drained. Amoxicillin/clavulanic acid was discontinued and the patient was switched to piperacillin/tazobactam. Contrast-enhanced neck CT (Fig. 2B) showed a multiloculated rim-enhancing fluid-attenuation lesion at the right anterior neck. A pressure effect causing the leftward displacement of the trachea and larynx and the obliteration of the right internal jugular vein was observed. The abnormal pyriform sinus tract was not identified. According to neck CT, an infected necrotic thyroid cancer was in the differential diagnosis. Due to the compressive symptoms, the possibility of malignancy, and the failure of aspiration, hemithyroidectomy was scheduled. Intraoperatively, there was a severe adhesion and normal tissue plane could not be identified. Deroofing and open drainage were performed in order to prevent a recurrent abscess and to obtain the tissue for diagnosis. Five days after the operation, histopathologic examination revealed an ill-defined cavity in the deep dermis and s.c. tissue. Part of an infundibular cyst of a hair follicle was observed in the specimen (Fig. 3A). Evidence of



**Figure 1**  
Anterior view of the patient's neck. At 2 weeks before visit (A) and at the first visit (B).



**Figure 2**  
Neck ultrasonography showed mixed echogenic multiloculated solid-cystic lesion containing echogenic/turbid fluid occupying at the right thyroid region with surrounding inflammatory change (A). Contrast-enhanced neck CT showed multiloculated rim-enhancing fluid-attenuation lesion at the right anterior neck with pressure effect to trachea, larynx, and right internal jugular vein (B).



**Figure 3**

Microscopic findings of the epidermoid cyst (Hematoxylin and eosin staining). (A) An ill-defined cavity in the deep dermis and s.c. tissue with the part hair follicle. (B) Evidence of extensive necrotizing inflammation, recent hemorrhage, and abscess formation are noted. No thyroid tissue was identified.

extensive necrotizing inflammation, recent hemorrhage, and abscess formation was also noted (Fig. 3B). Neither thyroid tissue nor foreign bodies were identified in the pathology specimen. These pathological results were compatible with a ruptured epidermoid cyst with severe inflammation and abscess formation. Repeated fine-needle aspiration of the right thyroid gland revealed no malignant cells. The pus culture grew *Parvimonas micra* and *Prevotella intermedia*, which are anaerobic bacteria. No aerobic bacteria were isolated.

## Outcome and follow-up

After the surgical procedure, the patient responded well to antibiotics. The fever and compressive symptoms were alleviated. After a week of admission, the patient was discharged home. No signs of recurrence were observed at the 3-month follow-up. However, his thyroid function tests showed subclinical hypothyroidism with a TSH level of 8.41  $\mu\text{IU/mL}$  (normal range: 0.3–4.1  $\mu\text{IU/mL}$ ), serum free T4 level of 1.11  $\mu\text{g/dL}$  (normal range: 0.8–1.8  $\mu\text{g/dL}$ ), and total T3 level of 126  $\text{ng/dL}$  (normal range: 60.7–176.7  $\text{ng/dL}$ ). At the 1-year follow-up, his TSH level was 6.53  $\mu\text{IU/mL}$  and the serum free T4 level was 1.26  $\mu\text{g/dL}$ . Follow-up neck ultrasonography showed a normal appearance of the thyroid gland.

## Discussion

EC, also known as epidermal cyst, epidermal inclusion cyst, inclusion cyst, and infundibular cyst, is the most common benign skin cyst and frequently occurs in the third and fourth decades of life. EC originates from the

ectoderm, which is composed of a stratified squamous epithelial lining (2). The cyst is formed when the skin around the infundibulum of a hair follicle is unable to shed normally. This abnormal shedding may be caused by skin trauma or infection. Superimposed infection and malignant transformation are rare. Symptoms of EC depend on the size and location of the cyst, with small ECs of the trunk typically asymptomatic. However, spontaneous cyst rupture can lead to bleeding, infection, or pain. Most cases of EC of the neck locate in the submental region and are often asymptomatic (2).

One useful sign to differentiate a thyroid mass from an EC is that the EC should move along with the skin, whereas a thyroid mass does not (3). However, this sign is not considered entirely specific and it is even more difficult when the EC becomes infected. As such, pain and inflammation may limit physical examination. Neck ultrasonography can help locate the lesion but has limited utility in the diagnosis of EC due to the non-specific ultrasound features. EC typically appears on ultrasonography as a well-defined anechoic cyst, but it can have heterogeneous echogenicity upon infection (4). The radiologic clue to differentiate between EC of the neck and the thyroid is the lining between the cyst wall and the thyroid gland. However, when the infection is extensive, the cyst wall that separates the thyroid and s.c. tissue may be obscured, leading to an erroneous diagnosis.

There are few previous reports of cervical EC mimicking thyroid neoplasm (5, 6, 7, 8, 9) and none of the cases had superimposed infection. Several authors have posited that EC represents one of the rare thyroid neoplasms, originating from mucosal sites due to the squamous metaplasia of the gland (5, 6, 7). On the other hand, others consider that EC is an extra-thyroidal neoplasm (8). The identification of the cyst wall is clear evidence in support of the notion that EC is of extra-thyroid origin. However, our case presented with superimposed infection and extensive inflammation, making the differentiation between the intra- and extra-thyroidal origin extremely difficult.

Our patient had abnormal thyroid function tests, supporting the diagnosis of thyroid abscess over EC abscess at the initial presentation. The explanation of the abnormal thyroid function tests in this patient may have been due to the inflammation surrounding the thyroid gland secondary to the infected cyst. This infection could directly invade the thyroid capsule, causing destructive thyroiditis. This mechanism has been proposed by a previous report, which revealed



a case involving an infected cervical thymic cyst that caused a perithyroidal abscess and eventually resulted in acute suppurative thyroiditis (9). Although thyroid abscess typically has normal thyroid function tests, a previous study showed that hyperthyroidism was reported in 12% of the patients and hypothyroidism was reported in up to 17% of the patients (10). One additional explanation of the abnormal thyroid function test in this patient is the co-incidence of thyroiditis. However, in this case, the unidentified thyroid cyst wall may be the clue, which favors the direct invasion of the EC over the co-incidence of thyroiditis.

In conclusion, EC abscess is a rare mimicker of thyroid abscess. As such, it is very challenging to distinguish EC abscesses from those involving the thyroid. Furthermore, infection and rupture of the EC at the neck region may interfere with thyroid function tests and lead to an erroneous diagnosis. In addition, physical examination and imaging have a limited role when infection occurs. Therefore, surgical management may be needed to establish a diagnosis and guide proper management.

#### Declaration of interest

The authors declare that there is no conflict of interest that could be perceived as prejudicing the impartiality of the research reported.

#### Funding

This research did not receive any specific grant from any funding agency in the public, commercial, or not-for-profit sector.

#### Patient consent

Written informed consent for publication of clinical details and/or clinical images was obtained from the patient.

#### Author contribution statement

W Chatchomchaun wrote the initial draft of the paper. Y Thewjitcharoen wrote the paper and contributed for discussion. All authors played a significant role in editing this report. V Veerasomboonin helped with the review of all radiological investigations. P Junyangdikul provided expert opinions on pathological examinations. W Chatchomchaun involved in the care of this patient and reviewed and discussed the case with T Himathongkam, an attending staff, and A Kanchanapituk, a surgeon, who guided this patient diagnosis and proper treatment. The authors thank S Nakasatien who had put much effort in the care of this patient.

#### References

- 1 Schwetschenau E & Kelley DJ. The adult neck mass. *American Family Physician* 2002 **66** 831–838.
- 2 James W, Berger T & Elston D. Epidermal nevi, neoplasms, and cysts. In *Andrews' Diseases of the Skin: Clinical Dermatology*, 11th ed., ch. 9, pp. 620–674. Saunders, 2011.
- 3 Higgins JC, Maher MH & Douglas MS. Diagnosing common benign skin tumors. *American Family Physician* 2015 **92** 601–607.
- 4 Hoang VT, Trinh CT, Nguyen CH, Chansomphou V, Chansomphou V & Tran TTT. Overview of epidermoid cyst. *European Journal of Radiology Open* 2019 **6** 291–301. (<https://doi.org/10.1016/j.ejro.2019.08.003>)
- 5 Choure DD, Nichat DP, Agarwal DS, Turabi DMA & Tayade DMB. Epidermal cyst presenting as a solitary thyroid nodule: a rare case report. *Journal of Medical Science and Clinical Research* 2015 **3** 7139–7142. (<https://doi.org/10.18535/jmscr/v3i8.39>)
- 6 Kuduban O. Epidermal inclusion cyst of thyroid gland. *Eurasian Journal of Medicine* 2015 **47** 78. (<https://doi.org/10.5152/eajm.2014.15>)
- 7 Rumberger LK, Mancini M, Curzon M & Orucevic A. Intrathyroidal epidermoid cyst associated with nodular Hashimoto's thyroiditis: a rare pathologic finding in a common clinical entity. *American Surgeon* 2014 **80** e205–e206.
- 8 Kannan S, Hedne N, Akila L & Kuppaswamy M. Epidermal inclusion cyst in the neck masquerading as a thyroid neoplasm. *Thyroid Research and Practice* 2015 **12** 32–34. (<https://doi.org/10.4103/0973-0354.147290>)
- 9 Ozaki O, Sugimoto T, Suzuki A, Yashiro T, Ito K & Hosoda Y. Cervical thymic cyst as a cause of acute suppurative thyroiditis. *Japanese Journal of Surgery* 1990 **20** 593–596. (<https://doi.org/10.1007/BF02471019>)
- 10 Yu EH, Ko WC, Chuang YC & Wu TJ. Suppurative *Acinetobacter baumannii* thyroiditis with bacteremic pneumonia: case report and review. *Clinical Infectious Diseases* 1998 **27** 1286–1290. (<https://doi.org/10.1086/514998>)

Received in final form 24 April 2020

Accepted 15 May 2020