

An extremely rare case of calcinosis cutis in human Cushing's disease

Najoua Rbiai¹, Ikram Mahroug¹, Nada Zizi^{2,3} and Hanane Latrech^{1,2}

¹Department of Diabetology and Endocrinology, Mohammed VI Hospital, ²Laboratory of Epidemiology, Clinical Research and Public Health, and ³Department of Dermatology, Mohammed VI Hospital, Faculty of Medicine and Pharmacy, Mohamed Ist University, Oujda, Morocco

Correspondence
should be addressed
to N Rbiai
Email
najwarbiai@gmail.com

Summary

Cushing's disease or pituitary adrenocorticotrophic hormone (ACTH)-dependent Cushing's syndrome is considered a rare condition. It is caused by hypersecretion of the ACTH by a pituitary adenoma that ultimately induces endogenous hypercortisolism by stimulating the adrenal glands. It is responsible for significant morbidity and mortality. The clinical signs and symptoms of hypercortisolism are usually common and non-specific including obesity, moon face, hypertension, hirsutism and facial plethora. The association between Cushing's disease and calcinosis cutis which is defined as dystrophic calcium deposition in the skin and subcutaneous tissues is extremely rare. To the best of our knowledge, it has never been described previously in humans, probably like a symptom or complication of chronic and severe hypercortisolism. In this paper, we report a case of a 30-year-old female diagnosed with Cushing's disease and presented bilateral leg's calcinosis cutis complicated with ulceration. The evolution was favorable and the complete cicatrization was obtained 12 months following the suppression of systemic glucocorticoid excess.

Learning points:

- Calcinosis cutis is common in autoimmune connective diseases. However, to our knowledge, it has never been reported in humans with Cushing's disease.
- Given the rarity of this association, the diagnostic approach to calcinosis cutis must exclude the other etiologies.
- Calcinosis cutis is challenging to treat with no gold standard therapy. In our case, the use of the combination of colchicine and bisphosphonates does not significantly improve the patient's outcomes. In fact, we suppose that without treating the endogenous hypercortisolism, the calcinosis cutis will not resolve.

Background

Cushing's disease was first described by Harvey Cushing in 1932 and represents by far the most common cause of Cushing's syndrome (1). It is caused by an adrenocorticotrophic hormone (ACTH) secreting pituitary tumor that causes increased cortisol secretion. Cushing's disease is associated with substantial morbidity and mortality and alters significantly the quality of life. Moreover, it is associated with an increased risk of metabolic, and cardiovascular manifestations, as well as respiratory disorders, psychiatric disturbances, osteoporosis and an increased risk of infections (2, 3). The

clinical findings are non-specific including weight gain, truncal obesity, moon face, striae, hirsutism, hypertension and glucose intolerance.

Calcinosis cutis or dystrophic soft-tissue calcification is reported in a few cases of autoimmune connective diseases such as systemic lupus erythematosus, scleroderma and polymyositis. To our knowledge, it has never been reported in humans with Cushing's disease.

However, all described cases were reported in veterinary medicine in dogs with endogeneous and iatrogenic hyperadrenocorticism with unclear pathogenesis. In this

paper, we report an illustrative patient with a complicated Cushing's disease that was presented to our department with extensive subcutaneous calcification in the lower extremities with severe ulceration and we discuss the clinical severity and difficult management of this association that was never described before in humans.

Case presentation

A 30-year-old woman was healthy until the age of 26, when she developed depression, sleep disorders and psychomotor retardation, which motivated the patient to consult a neuropsychiatrist after a long period of reluctance. The patient was then referred to our department because of high clinical suspicion of Cushing's syndrome. Physical examination was notable for Cushingoid facies, truncal obesity with a BMI at 27 kg/m², hirsutism with Ferriman-Gallway score at 22, secondary amenorrhea, hypertension (200/120 mmHg) and hyperglycemia (2 g/L), striae over the trunk and extremities and pedal edema (Fig. 1). The joint mobility was limited because of pain, and neurological and vascular examinations were normal.

The patient presented with leg pain and reduced ambulation for 6 months. Four months later, she developed a hard cutaneous plaque overlying with the area of skin ulceration in the right leg measuring 6 cm and extruding calcium salts (Fig. 2). Her physical examination revealed cyanosis toes as shown in Fig. 3. Our patient had no history of any inciting traumatic event.

Investigation

The laboratory assays confirmed the diagnosis of Cushing's disease after the following measurements: (i) Three elevated measurements of urinary free cortisol (UFC) on complete 24 h urine collection with appropriate urinary creatinine levels at 1460 µg/24 h, 927 µg/24 h and 892 µg/24 h, respectively (normal, 4.30–176 µg/24 h; RIA); (ii) sleeping midnight serum cortisol elevated at 27.6

µg/dL (RIA); (iii) lack of suppression on 1-mg overnight dexamethasone suppression test (ONDST) and on low-dose dexamethasone suppression test. The highly-sensitive serum ACTH was normal at 35.6 pg/mL (normal, 10.3–48.3; electrochemiluminescence immunoassay), with more than 50% UFC suppression from the baseline (UFC after 8-mg ONDST at 15 µg/24 h).

The pituitary MRI does not identify a microadenoma; therefore, the diagnosis of Cushing's disease with negative imaging was retained. The CT scan of the adrenal gland shows right adrenal gland hyperplasia. The arterial and venous Doppler ultrasound of the lower extremities were without abnormalities.

Immunological tests including anti-nuclear antibodies, anti-DNA antibodies, anti-U1RNP antibodies and rheumatoid factor were negative. Blood-calcium and phosphorus levels were normal at 92 mg/L (89–102) and 23 mg/L (20–45), respectively. Serum 25(OH) vitamin D levels were insufficient at 12 ng/mL. The diagnosis of calcinosis cutis was confirmed by skin biopsy. The histopathological examination showed calcifications in the hypodermis fat tissue (Fig. 4). Legs X-ray and CT scan detected remarkable cutaneous and subcutaneous calcifications distributed diffusely on the patient's legs (Fig. 5). The patient was found to have osteoporosis on bone densitometry (T-score: lumbar vertebrae (L2–L4): –2, 80 / femoral bone: –2, 50) (Z-score: lumbar vertebrae (L2–L4): –3, 10/ femoral bone: –2, 60).

Treatment

Blood pressure was controlled with triple therapy including amlodipine 5 mg/day, bisoprolol 10 mg/day and ramipril 10 mg/day. Glycemia was also well controlled under insulin and metformin. The colchicine was prescribed at a dose of 1 mg per day and risedronate at 35 mg was taken once a week without any remarkable improvement of pain or ulceration. After a multidisciplinary board meeting, we decided to perform bilateral adrenalectomy to treat this

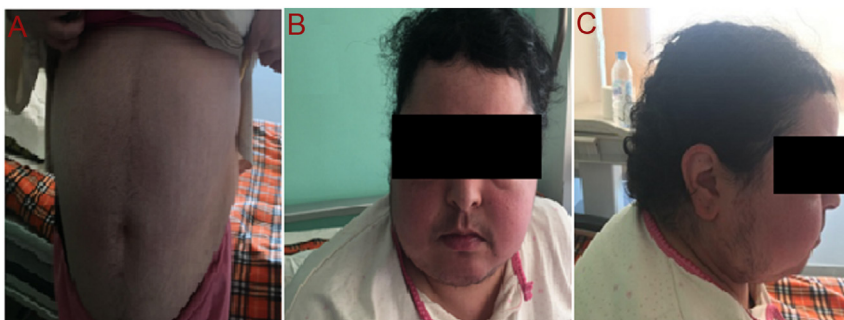

Figure 1
(A) Stretch striae on the abdomen and proximal portion of the lower limbs, abdominal adiposity, contrasting with thin legs, (B) facial swelling, erythrosis and dorso-cervical pad of fat, (C) marked hirsutism.

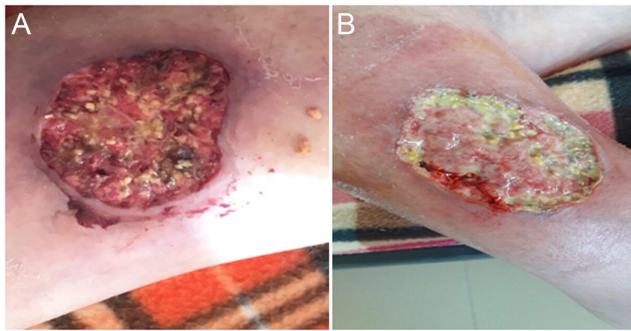

Figure 2
Cutaneous ulceration with focal extrusion of chalky granules.

severe and complicated Cushing's disease. To alleviate the associated signs and symptoms of Cushing's syndrome, a preparation was started by using ketoconazole (600 mg daily). FUC values returned to normal within 3 weeks after treatment with ketoconazole, and the ulceration was stable, less painful and less inflamed. The surgery went well without any complications.

The patient received hydrocortisone at a dose of 25 mg per day and fludrocortisone (astonin ½ tablet taken twice daily) with adapted therapeutic education.

Outcome and follow-up

After the suppression of systemic glucocorticoid excess by using ketoconazole and bilateral adrenalectomy, the

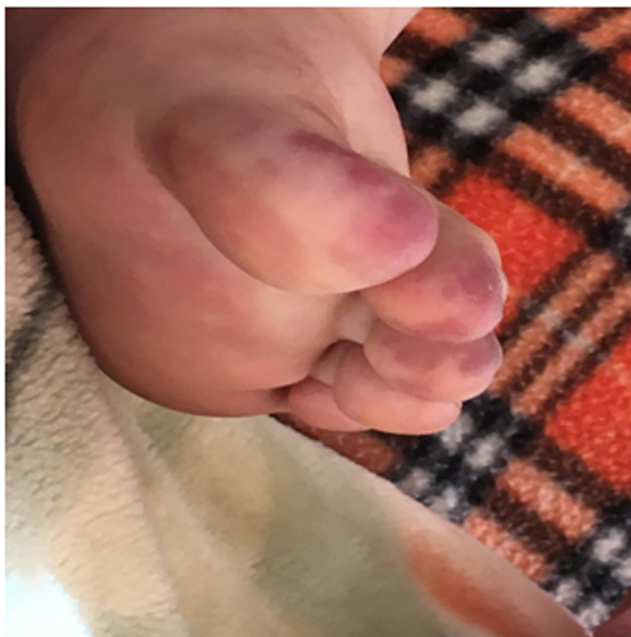

Figure 3
Left cyanosis toes.

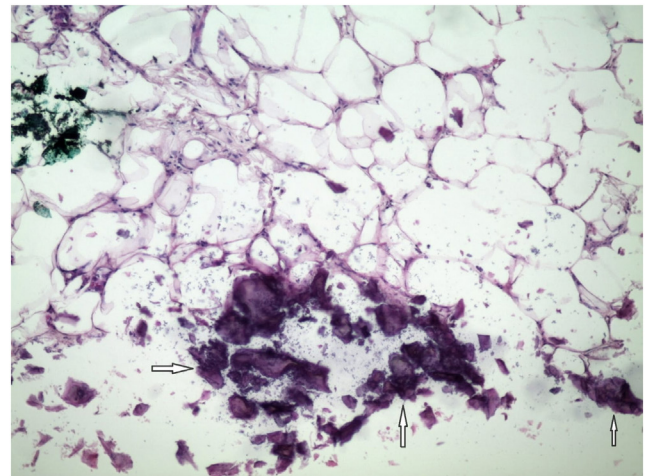


Figure 4
Histopathology of calcinosis cutis. Biopsy showing calcifications in the hypodermis fat tissue (hematoxylin–eosin stain; 100×).

evolution was favorable with regression of clinical signs of Cushing's syndrome with a complete cicatrization of the ulceration after 12 months of the surgery (Fig. 6).

The blood pressure was well controlled under a monotherapy of amlodipine 5 mg. The glycemic control was satisfactory under only 1 g of metformin as shown in the continuous glucose monitoring. Moreover, the control of bone densitometry at 1 year shows osteopenia with a T-score of -1.5 for L1-L4, -1.4 for femoral bone and a Z-score of -1.2 for L1-L4, -1.1 for femoral bone.

Discussion

Calcinosis cutis is a rare disorder characterized by aberrant calcium deposition in the skin and subcutaneous tissue. It is usually divided into the following four separate categories: dystrophic, metastatic, iatrogenic and idiopathic. Moreover, it is commonly reported in autoimmune connective tissue diseases, especially in dermatomyositis and systemic sclerosis and can be associated with a risk of morbidity and functional disability (4, 5). In the present case, the patient was diagnosed with severe Cushing's disease with a diffuse distribution of calcinosis cutis in bilateral legs complicated with large ulceration extruding calcium salts.

The severity of calcinosis cutis varies from localized nodules to severe debilitating lesions which can ulcerate, extrude calcium salts and predispose to several infections. The physiopathology of calcinosis cutis is not completely clear. The mechanism initiating the process of calcification varies among the subtypes of calcinosis. The dystrophic subtype results when calcium is deposited in the

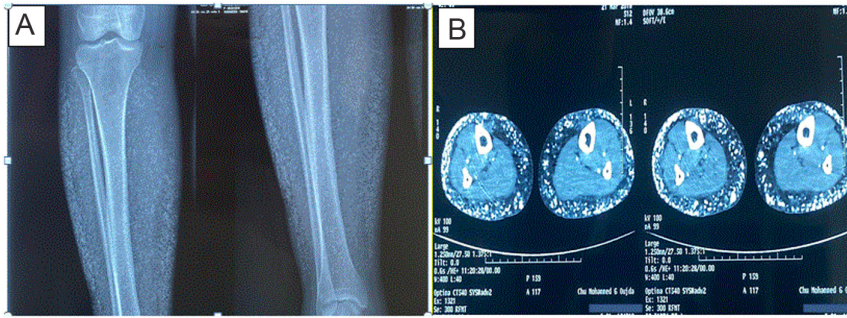


Figure 5
(A) Nodular and reticular radiological patterns of calcinosis cutis in bilateral legs in association with Cushing's disease. (B) CT angiography of lower limbs in cross-section showing diffuse nodular calcifications.

cutaneous tissue after chronic tissue damage or defective collagen synthesis. This subtype shows serum calcium and phosphate levels are within normal ranges and is observed in different degenerative, collagen vascular and congenital disorders.

Metastatic calcinosis is a rare condition that may occur in cases of hypercalcemia or hyperphosphatemia which leads to aberrant calcification; there is a correlation between the importance of hyperphosphatemia and the degree of the calcifications, and the normalization of the calcium and phosphate serum levels improves the lesions. Iatrogenic calcinosis may be associated with a complication of therapeutic or diagnostic procedures such as subcutaneous injection of calcium-containing heparins, extravasation of calcium-containing intravenous solutions, and following electroencephalographic and electromyographic examinations with electrodes containing calcium chloride paste (6). Idiopathic calcification occurs without any underlying tissue damage or systemic disorder.

Many type 2 diabetes mellitus (T2DM) patients may have medial arteriolar calcification which is the most prevailing form of vascular calcification in T2DM and results in ischemic subcutaneous necrosis with vulnerable skin ulcerations and high mortality. The risk factors for the medial artery calcification in T2DM are vibration perception, long duration of diabetes and poor glycemic control (7). The skin lesions of calciphylaxis present as painful violaceous areas in the extremities, proximal medial thighs, anterior abdomen and lateral flank areas,

the breast in females and frequently overlies or are adjacent to subcutaneous tumorous calcifications in areas of increased adipose tissue. They then progress to blackish eschars, which later reveal themselves on a granulating bed and gradually enlarge and ulcerate at the periphery (8). In our case, diabetes was recently discovered and perfectly controlled. The check-up of degenerative complications was normal. We believe that the cause of calcinosis cutis is glycogenic and protein catabolic activity and local ischemia induced by pressure exerted by hypertrophic fat cells associated with hypercortisolism.

Plain radiography is very sensitive to detecting calcinosis and is recommended for initial imaging of calcinosis with high accuracy as CT scan (9). The nodular morphological patterns of calcinosis are the most frequently reported in autoimmune connective tissue disease (ACTD). However, multiple other morphological features of calcification may occur alone or in association with ACTD such as nodular, linear, reticular and amorphous patterns (9). In our case, the calcifications were essentially nodular with a spectacular radiological improvement (Fig. 7) with a complete cicatrization of the ulceration after deleting systemic glucocorticoid excess by bilateral adrenalectomy.

Calcinosis cutis is challenging to treat with no gold standard therapy available to date. Several therapeutic options have demonstrated improved outcomes such as calcium channel blockers that can correct the abnormal imbalance of intracellular calcium concentration and can lead to crystal formation. The use of colchicine as an antimicrotubule agent was found to be beneficial

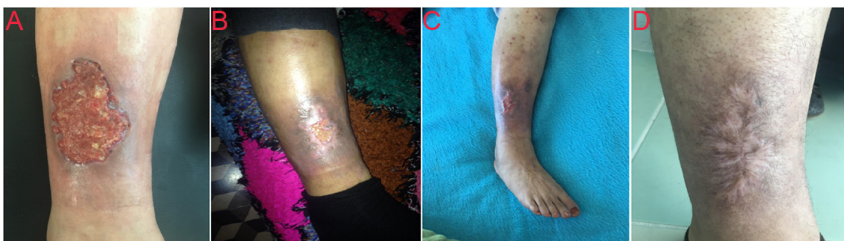

Figure 6
Evolution of the ulceration after 3 months (A), 6 months (B), 9 months (C) and after 1 year of the adrenalectomy and treatment with colchicine and bisphosphonate (D).

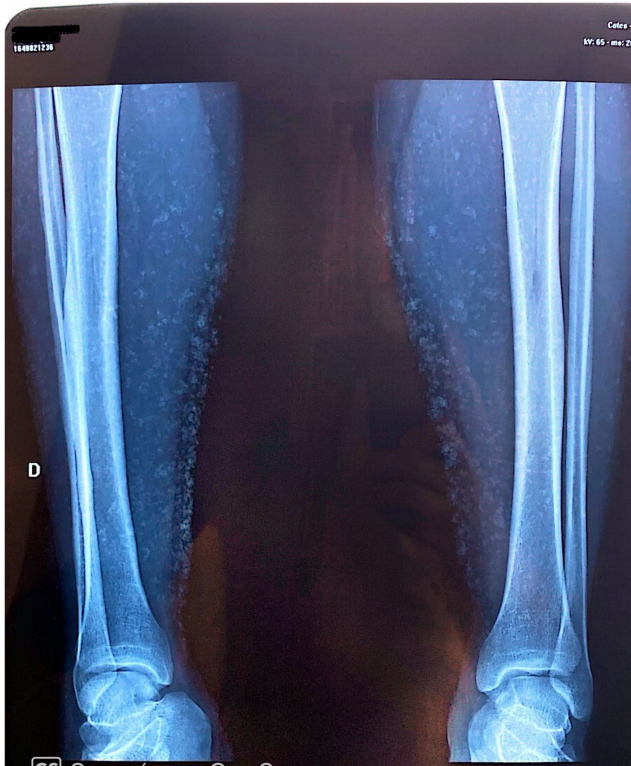

Figure 7
X-ray follow-up images showing radiological improvement.

in reducing calcinosis by acting on inflammation. Minocycline can be also prescribed based on its combined effects on inflammatory mechanisms and matrix metalloproteinase enzymes as well as calcium chelation. In addition, intravenous use of immunoglobulins may impact the prognosis by decreasing inflammation, probably by inhibiting macrophage functions. Similarly, bisphosphonates may be proposed for calcinosis cutis as they have effects on the inhibition of calcium turnover. Surgical excision of the nodule is an option, but it is associated with a high risk of recurrence (10).

In our case, the use of the combination of colchicine and bisphosphonates does not significantly improve our patient's outcomes. The lesion was very painful, greater in size and deep. In fact, we suppose that without treating the underlying cause, which is the endogenous hypercortisolism in the present case, the calcinosis cutis will not resolve. The precise mechanisms underlying diffuse subcutaneous calcifications in association with Cushing's disease are unclear. To the best of our knowledge, it has never been described before in humans. A large cohort of 46 dogs documented endogenous hyperadrenocorticism as the second cause for calcinosis cutis after iatrogenic

hyperadrenocorticism (11). The role of cortisol in the development of calcinosis cutis is considered as a result of its glucogenic and protein catabolic activity and local ischemia induced by pressure exerted by hypertrophic fat cells associated with hypercortisolism (12). It seems that the rearrangement of the molecular structure of proteins leads to dystrophic calcification by the development of an organic matrix that attracts and binds calcium (12). To our knowledge, this is the first case of calcinosis cutis never described before in severe Cushing's disease probably as a new clinical symptom or complication of hypercortisolism in the human case. Therefore, the management of this association is difficult due to the painful nature and progressive evolution of clinical features of calcinosis cutis with the severity and delayed diagnosis of Cushing's syndrome.

Conclusion

Calcinosis cutis is reported mainly in autoimmune connective disease. To the best of our knowledge, all cases of calcinosis cutis in association with Cushing's disease were reported in dogs with endogeneous and iatrogenic hyperadrenocorticism. The exact mechanism underlying the process of calcification is not very clear. Several treatments have been tried, but no gold standard therapy is available to date. Further studies are needed to clarify the precise pathogenesis and her resolution by the control of hypercortisolism.

Declaration of interest

The authors declare that there is no conflict of interest that could be perceived as prejudicing the impartiality of the research reported.

Funding

This work did not receive any specific grant from any funding agency in the public, commercial, or not-for-profit sector.

Patient consent

The authors confirm that written informed consent has been obtained from the patient for publication of the case report and accompanying images.

Author contribution statement

N Rbiai was the treating Resident Medical Officer during the patient's inpatient stay. She prepared the initial draft of the article, co-ordinated with co-authors and prepared the final manuscript. Co-authors I Mahroug, N Zizi and H Latrech were responsible for manuscript review.



References

- 1 Bertagna X, Guignat L, Groussin L & Bertherat J. Cushing's disease. *Best Practice and Research: Clinical Endocrinology and Metabolism* 2009 **23** 607–623. (<https://doi.org/10.1016/j.beem.2009.06.001>)
- 2 Steffensen C, Bak AM, Rubeck KZ & Jørgensen JO. Epidemiology of Cushing's syndrome. *Neuroendocrinology* 2010 **92** (Supplement 1) 1–5. (<https://doi.org/10.1159/000314297>)
- 3 Jeffcoate WJ, Silverstone JT, Edwards CR & Besser GM. Psychiatric manifestations of Cushing's syndrome: response to lowering of plasma cortisol. *Quarterly Journal of Medicine* 1979 **48** 465–472.
- 4 Boulman N, Slobodin G, Rozenbaum M & Rosner I. Calcinosis in rheumatic diseases. *Seminars in Arthritis and Rheumatism* 2005 **34** 805–812. (<https://doi.org/10.1016/j.semarthrit.2005.01.016>)
- 5 Balin SJ, Wetter DA, Andersen LK & Davis MD. Calcinosis cutis occurring in association with autoimmune connective tissue disease: the Mayo Clinic experience with 78 patients, 1996–2009. *Archives of Dermatology* 2012 **148** 455–462. (<https://doi.org/10.1001/archdermatol.2011.2052>)
- 6 Johnson RC, Fitzpatrick JE & Hahn DE. Calcinosis cutis following electromyographic examination. *Cutis* 1993 **52** 161–164
- 7 Everhart JE, Pettitt DJ, Knowler WC, Rose FA & Bennett PH. Medial arterial calcification and its association with mortality and complications of diabetes. *Diabetologia* 1988 **31** 16–23. (<https://doi.org/10.1007/BF00279127>)
- 8 Hayden MR, Tyagi SC, Kolb L, Sowers JR & Khanna R. Vascular ossification – calcification in metabolic syndrome, type 2 diabetes mellitus, chronic kidney disease, and calciphylaxis – calcific uremic arteriopathy: the emerging role of sodium thiosulfate. *Cardiovascular Diabetology* 2005 **4** 4. (<https://doi.org/10.1186/1475-2840-4-4>)
- 9 Shahi V, Wetter DA, Howe BM, Ringler MD & Davis MDP. Plain radiography is effective for the detection of calcinosis cutis occurring in association with auto-immune connective tissue disease. *British Journal of Dermatology* 2014 **170** 1073–1079. (<https://doi.org/10.1111/bjd.12785>)
- 10 Fabreguet I, Saurat JH, Rizzoli R & Ferrari S. Calcinose cutanée associée aux connectivites. *Revue Medicale Suisse* 2015 **11** 668–672.
- 11 Doerr KA, Outerbridge CA, White SD, Kass PH, Shiraki R, Lam AT & Affolter VK. Calcinosis cutis in dogs: histopathological and clinical analysis of 46 cases. *Veterinary Dermatology* 2013 **24** 355–361. (<https://doi.org/10.1111/vde.12026>)
- 12 Berry CR, Ackerman N & Monce K. Pulmonary mineralization in four dogs with Cushing's syndrome. *Veterinary Radiology and Ultrasound* 1994 **35** 10–16. (<https://doi.org/10.1111/j.1740-8261.1994.tb00170.x>)

Received in final form 5 May 2022

Accepted 10 May 2022