

Accidental exposure to glimepiride from adulterated medication resulting in severe hypoglycaemia

Annabelle G Hayes^{1,2}, Mahesh M Umaphathysivam^{1,2} and David J Torpy^{1,2}

¹Endocrine and Metabolic Unit, Royal Adelaide Hospital, Adelaide, South Australia, Australia and ²University of Adelaide, Adelaide, South Australia, Australia

Correspondence
should be addressed
to A G Hayes
Email
annabelle.hayes@sa.gov.au

Summary

Sulphonylureas are insulinotropic and are not only useful in patients with diabetes but also act in non-diabetic individuals where hypoglycaemia and hyperinsulinism mimic insulinoma. We present a 63-year-old man who presented with inadvertent sulphonylurea-induced life-threatening hypoglycaemia on two occasions, resulting in hazardous and invasive investigation. Biochemistry revealed endogenous hyperinsulinaemia, with elevated serum c-peptide and insulin concentrations during symptomatic hypoglycaemia, and plasma glucose of 1.7 mmol/L. There was no history of sulphonylurea use prompting anatomical insulinoma studies to locate an insulinoma. However, a routine plasma insulinoma screen-detected glimepiride. Directed history implicated a medication taken for erectile dysfunction prior to disturbed consciousness, with alcohol. The tablets, obtained online, were analysed by mass spectrometry and contained tadalafil and dapoxetine as advertised but also contained glimepiride.

Learning points:

- Symptomatic unexplained hypoglycaemia requires investigation with plasma glucose level, c-peptide, insulin level, pro-insulin, beta-hydroxybutyrate, and a sulphonylurea screen regardless of known exposure to sulphonylureas.
- Consider contamination of alternative or undisclosed medication, including PDE-5 inhibitor erectile dysfunction drugs.
- Concomitant alcohol may impair glycogenolysis and gluconeogenesis, exacerbating hypoglycaemia.

Background

The use of sulphonylureas (SU) in diabetes mellitus aims to alleviate reduced pancreatic beta-cell mass or function. SUs act via a specific SU receptor to close pancreatic beta-cell ATP-sensitive K⁺ channels with consequent depolarisation and insulin release (1, 2). SU administration in patients without diabetes is typically accidental, for example, misadventure in a young child or medication dispensing error commonly resulting in hypoglycaemia requiring hospital admission (4). Their unannounced presence in medication sold as erectile dysfunction treatment has previously been fatal, though very few recent cases have been reported (2).

This case demonstrates the ongoing risk of SU-contaminated erectile dysfunction medication and avoiding unnecessary investigation and highlights the value of the SU assay in unexplained hypoglycaemia.

Case presentation

A 63-year-old man, a healthcare worker, presented to the Emergency Department with profound, symptomatic hypoglycaemia without a history of diabetes or use of known hypoglycaemic agents. He complained of

diaphoresis, weakness, ataxia, visual blurring, and palpitations without loss of consciousness. Symptoms were partially responsive to oral carbohydrates but recurred rapidly. His medical history included gastroesophageal reflux for which he took esomeprazole 20 mg as required and no regular medication. He had a BMI of 28.4 kg/m². This was the second such episode for this patient who was admitted to another hospital 3 months prior, requiring a glucose infusion for several days.

The event occurred the day following a night of moderate alcohol intake (5–7 std drinks) and 3 h after a moderate morning meal, during light exercise. There was no loss of consciousness and symptoms were temporarily controlled with orange juice. In the emergency department, he received several treatments of 25–50 mL 50% dextrose intravenously and two doses of glucagon 1 mg intramuscularly. Ongoing treatment was required with 10% dextrose at a rate of 200 mL/h to maintain capillary blood glucose of 3.3–10.4 mmol/L for 48 h prior to weaning to 100 mL/h for a further 48 h (Fig. 1).

Investigation

A brief, observed interruption of the dextrose infusion on day 2 of admission resulted in hypoglycaemia to 1.7 mmol/L within 15 minutes. The patient was profoundly symptomatic. Blood samples were taken for glucose, c-peptide, glucagon, beta-hydroxybutyrate, pro-insulin, insulin, and a sulphonylurea screen. Cortisol and thyroid

function were normal and no serum insulin antibodies were detected (Table 1).

High-resolution CT failed to identify a pancreatic lesion, and similarly, 68 Gallium DOTATATE PET arranged after his initial presentation did not detect a GaTate avid neuroendocrine tumour.

Given the lack of apparent pharmacological interference, very high c-peptide, and insulin levels, there was high suspicion of insulinoma. He underwent endoscopic pancreatic ultrasound which discovered a 7 mm equivocal poorly defined mass in the pancreatic head. Biopsy demonstrated normal tissue.

Sulphonylurea screening conducted on mass spectrometry in the sample on day 2 was positive for glimepiride. On further directed discussion, the patient disclosed the use of an erectile dysfunction medication acquired online. The medication, supplied by the patient, had been advertised as ‘Tadapox’, reportedly containing tadalafil 20 mg (a phosphodiesterase 5 inhibitor) for vasodilatory effects and 60 mg dapoxetine (a selective serotonin reuptake inhibitor) to delay ejaculation. It appeared as a lime green, small, circular tablet packaged in foil with these details inscribed. The tablet was tested by mass spectrometry for the presence of glimepiride.

Mass spectrometry identified three substances in the tablets: tadalafil, dapoxetine, and glimepiride. The patient reportedly took ¼ to ½ a tablet the night prior to admission and on a few other occasions previously. The two hypoglycaemic episodes were associated with alcohol intake.

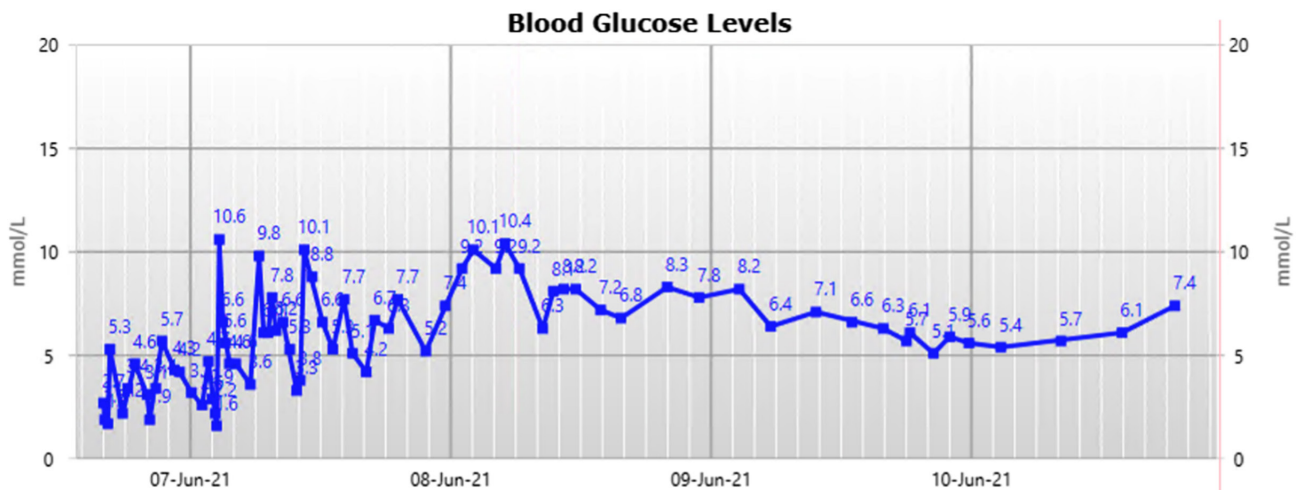


Figure 1 Capillary blood glucose trends over the course of the patient’s hospital admission commencing from presentation to the emergency department.



Table 1 Relevant laboratory findings.

	Day 1, 16:31 h	Day 1, 17:55 h	Day 1, 20:29 h	Day 2, 10:45 h
Glucose (3.2–5.5 mmol/L)	1.9	2.2 (capillary)	3.0	1.7
C-peptide (366–1466 pmol/L)	13 472	15 329	16 906	6464
Insulin (0–12 mU/L)	339	718	959	131
Pro-insulin (<13.3 pmol/L)				>100
Beta-hydroxybutyrate (0–0.29 mmol/L)				<0.10

Treatment

Intravenous glucose infusion was required for a total of 4 days. After confirmation of unintentional ingestion of sulphonylurea tablets, its use was discontinued and no further specific treatment was required.

Outcome and follow-up

The patient remained asymptomatic after discontinuation of the responsible medication.

Discussion

This study reports the second of two life-threatening episodes of hypoglycaemia followed by unintentional self-poisoning with glimepiride in this patient. Concurrent alcohol ingestion may have accentuated the risk through the inhibition of glycogenolysis (6). Without the use of a sulphonylurea assay, this patient may have been subject to invasive intraabdominal ultrasound or hazardous partial pancreatectomy. Production of medications sold online through non-approved means may be adulterated with pharmacologic agents with unintended consequences.

The medication in question was marketed as ‘Tadapox’, reportedly containing 20 mg tadalafil and 60 mg of dapoxetine, a PDE-5 inhibitor and SSRI. The medication was obtained without a prescription from an online site ‘smartfinil.com’, where it advertises increased potency and duration of erection with delayed ejaculation. The site quotes rapid onset of action within 20–30 min and prolonged duration of action for 36 hours, recommending only a quarter of the tablet considering its ‘power’ and increasing as necessary. It warns against use in cardiovascular disease, renal disease, and coadministration with antihypertensives, psychotropics, or alcohol. Interestingly, the site advises avoiding ‘extra calories’ as this will reportedly reduce efficacy of the medication.

Adulteration of this medication with an unknown quantity of glimepiride has been proven, though a longer

duration of effect was demonstrated in this case than would typically be expected when used at usual doses in type 2 diabetes. Glimepiride, a second-generation sulphonylurea, reaches a peak plasma concentration after 2–4 h and typically lasts up to 24 h. It is primarily metabolised by the liver as active M1 metabolite and subsequently the inactive M2 metabolite before excretion mostly by the kidneys (7, 8).

As compared to glibenclamide, it carries a lower risk of hypoglycaemia due to comparatively preserved counter-regulatory response at 8.9–20% in a diabetic population. It is also thought to stimulate lipogenesis and glycogenesis via increased GLUT4 translocation (7).

While K-ATP channels have been found in corpus cavernosum, vasodilatory effect benefit in erectile dysfunction has not been proven, despite coadministration with a PDE-5 inhibitor (6).

A likely explanation for the remoteness of the ‘Tadapox’ consumption from the hypoglycaemic event is the consumption of alcohol. Alcohol is known to reduce hepatic gluconeogenesis and glycogenolysis, limiting the efficacy of counter-regulatory responses in starvation states or hypoglycaemia (5, 6).

Furthermore, alcohol can inhibit hepatic metabolism of glimepiride, prolonging its duration of action (6).

Sulphonylureas have been long appreciated to cause hypoglycaemia in those with and without diabetes mellitus. Most of these cases are in accidental ingestion by young children or dispensing error (1, 4). However, there has been precedent for sulphonylurea adulterated medication sold without prescription as sexual performance enhancing medication (2, 3).

A large outbreak of hypoglycaemia due to counterfeit Cialis (tadalafil) and herbal medicine containing varying doses of glyburide, tadalafil, and sibutramine resulted in 150 hospitalisations and 4 deaths in Singapore in early 2008. At a similar time, herbal medication sold in Hong Kong for sexual performance enhancement also contained large quantities of sulphonylurea leading to a further 97 cases, including 3 deaths (2). A close study of a similar case in 2010 demonstrated persistently elevated c-peptide and insulin levels for 9 days post-ingestion (3). Since 2010, few additional cases have been reported.



While the doses reported in these articles appear to be too large to be accidental contamination, the motivation for the addition of sulphonylurea is unclear. It has previously been appreciated that testosterone levels are low in men with type 2 diabetes mellitus, impairing sexual desire and performance (9). It has also been suggested that the use of sulphonylureas in type 2 diabetes may have an effect of increasing testosterone, particularly when compared to metformin (10). Further studies have investigated direct effect of sulphonylureas on the corpus cavernosum via local K-ATP channels. These studies have been very small and overall data are inconclusive but more suggestive of benefit of improved glycaemic control (9). Perhaps this underlies the addition of glimepiride to tadapox, although it is unclear why this is not a listed ingredient.

Declaration of interest

The authors declare that there is no conflict of interest that could be perceived as prejudicing the impartiality of the research reported.

Funding

This work did not receive any specific grant from any funding agency in the public, commercial, or not-for-profit sector.

Patient consent

This report has been prepared for publication with full informed consent from the patient. A copy of written consent has been obtained for future reference.

Author contribution statement

All three authors provided or directed ward care, investigation and management for the patient. The manuscript draft was prepared by A G H

and reviewed by M M U. D J T critically reviewed and supervised the overall preparation of the manuscript and care of the patient.

References

- 1 Basit A, Riaz M & Fawwad A. Glimepiride: evidence-based facts, trends, and observations (GIFTS). [corrected]. *Vascular Health and Risk Management* 2012 **8** 463–472. (<https://doi.org/10.2147/HIV.S33194>)
- 2 Langtry HD & Balfour JA. Glimepiride: a review of its use in the management of type 2 diabetes mellitus. *Drugs* 1998 **55** 563–584. (<https://doi.org/10.2165/00003495-199855040-00007>)
- 3 Klonoff DC, Barrett BJ, Nolte MS, Cohen RM & Wyderski R. Hypoglycemia following inadvertent and factitious sulfonylurea overdoses. *Diabetes Care* 1995 **18** 563–567. (<https://doi.org/10.2337/diacare.18.4.563>)
- 4 Chan TY. Outbreaks of severe hypoglycaemia due to illegal sexual enhancement products containing undeclared glibenclamide. *Pharmacoepidemiology and Drug Safety* 2009 **18** 1250–1251. (<https://doi.org/10.1002/pds.1880>)
- 5 van de Wiel A. Diabetes mellitus and alcohol. *Diabetes/Metabolism Research and Reviews* 2004 **20** 263–267. (<https://doi.org/10.1002/dmrr.492>)
- 6 Cignarelli A, Genchi VA, D'Oria R, Giordano F, Caruso I, Perrini S, Natalicchio A, Laviola L & Giorgino F. Role of glucose-lowering medications in erectile dysfunction. *Journal of Clinical Medicine* 2021 **10** 2501. (<https://doi.org/10.3390/jcm10112501>)
- 7 Oba-Yamamoto C, Takeuchi J, Nakamura A, Takikawa R, Ozaki A, Nomoto H, Kameda H, Cho KY, Atsumi T & Miyoshi H. Combination of alcohol and glucose consumption as a risk to induce reactive hypoglycemia. *Journal of Diabetes Investigation* 2021 **12** 651–657. (<https://doi.org/10.1111/jdi.13375>)
- 8 Bansal N & Weinstock RS. Non-diabetic hypoglycemia. In *Endotext*. Eds KR Feingold, B Anawalt, A Boyce, G Chrousos, WW de Herder, K Dhatariya, K Dungan, JM Hershman, J Hofland, S Kalra, et al. South Dartmouth (MA): MDText.com, Inc., 2000.
- 9 Chaubey SK, Sangla KS, Suthaharan EN & Tan YM. Severe hypoglycaemia associated with ingesting counterfeit medication. *Medical Journal of Australia* 2010 **192** 716–717. (<https://doi.org/10.5694/j.1326-5377.2010.tb03710.x>)
- 10 Al-Kuraishy HM & Al-Gareeb AI. Erectile dysfunction and low sex drive in men with type 2 DM: the potential role of diabetic pharmacotherapy. *Journal of Clinical and Diagnostic Research* 2016 **10** FC21–FC26. (<https://doi.org/10.7860/JCDR/2016/19971.8996>)

Received in final form 25 February 2022

Accepted 21 April 2022