

An incidental finding behind adrenal incidentaloma

Filippo Crimi^{1,2}, Giulio Barbiero², Irene Tizianel^{1,3}, Laura Evangelista^{1,4} and Filippo Ceccato^{1,3}

¹Department of Medicine DIMED, University of Padova, Padova, Italy, ²Institute of Radiology, ³Endocrine Disease Unit, and ⁴Nuclear Medicine Unit, University-Hospital of Padova, Padova, Italy

Correspondence should be addressed to F Ceccato
Email
filippo.ceccato@unipd.it

Summary

A 61-year-old man went to the Emergency Department with left upper abdominal quadrant pain and low-grade fever, as well as a loss of weight (3 kg in 6 weeks). A solid-cystic lesion in the left adrenal lodge was discovered by abdominal ultrasonography. A slight increase in the serum amylase with normal lipase was observed, but there were no signs or symptoms of pancreatitis. A contrast-enhanced CT revealed a tumor that was suspected of adrenocortical cancer. Therefore, he was referred to the endocrine unit. The hormonal evaluation revealed no signs of excessive or inadequate adrenal secretion. To characterize the mass, an MRI was performed; the lesion showed an inhomogeneous fluid collection with peripheral wall contrast-enhancement, as well as a minor 18-fluorodeoxyglucose uptake at PET/CT images. The risk of primary adrenal cancer was minimal after the multidisciplinary discussion. An acute necrotic collection after focal pancreatitis was suspected, according to the characteristics of imaging. Both CT-guided drainage of the necrotic accumulation and laboratory analysis of the aspirated fluid confirmed the diagnosis.

Learning points:

- Different types of expansive processes can mimic adrenal incidentalomas.
- Necrotic collection after acute focal pancreatitis could be misdiagnosed as an adrenal mass, since its CT characteristics could be equivocal.
- MRI has stronger capacities than CT in differentiating complex lesions of the adrenal lodge.
- A multidisciplinary approach is fundamental in the management of patients with a newly discovered adrenal incidentaloma and equivocal/suspicious imaging features (low lipid content and size >4 cm).

Background

A unique case of necrotic collection from localized pancreatitis that mimicked an adrenal incidentaloma and was mistaken as adrenocortical cancer by CT scan is presented. The patient's disease was correctly diagnosed thanks to a comprehensive multidisciplinary approach, preventing unnecessary surgery.

Adrenal incidentalomas are adrenal neoplasms discovered during an imaging procedure not performed for suspected adrenal disease; their prevalence is

age-dependent, and the majority of them are non-secreting benign cortical adenomas. The radiological evaluation should help the physicians to differentiate benign adenomas from malignant lesions (especially adrenocortical carcinomas and metastasis). In unenhanced CT, lipid-rich benign cortical adenomas are characterized by an attenuation value <10 Hounsfield Unit (HU).

If imaging and radiological evaluation remain equivocal, European Guidelines on adrenal

incidentalomas suggest adrenal biopsy, which should only be performed by experienced radiologists after ruling out a pheochromocytoma. Nonetheless, the procedure is of no use to differentiate a benign vs a malignant cortical lesion, and it should be considered to confirm metastasis from extra-adrenal cancer.

Case presentation

A 61-year-old man presented to the emergency department with a history of left upper abdominal quadrant pain. In the ultrasound examination, a solid-cystic mass in the left adrenal lodge of 6 cm, nearby the pancreas and left kidney, was depicted. The patient underwent a contrast-enhanced CT examination that confirmed a mainly cystic mass with thick contrast-enhanced septa in the context (black arrowhead) in the left adrenal lodge, with the suspicion of pancreatic and kidney involvement (Fig. 1, panel A). At an unenhanced CT scan, the mean density of the adrenal lesion was 23 HU. The radiologist hypothesized an adrenocortical carcinoma; therefore, the patient was referred to a third-level endocrine unit.

Investigation

After multidisciplinary discussion, blood tests, endocrine assessment, a contrast-enhanced MRI and a 18-fluorodeoxyglucose (18-FDG) PET/CT were suggested and performed. MRI was indicated in order to better characterize the lesion, while FDG PET/CT was performed in order to exclude an abscessualized adrenal carcinoma, that should present areas of high intra-lesional FDG uptake.

The blood examination excluded both cortical and medullary adrenal hyperfunction (serum cortisol after dexamethasonetest 28 nmol/L, normal aldosterone-to-renin

ratio, normal urinary fractionated metanephrines and free cortisol); a slight increase in the serum amylase with normal lipase was detected (137 U/L, normal range <125 and 39 U/L, normal value <78, respectively).

The MRI examination showed a large liquid lesion in T2-weighted images (Fig. 1, panel B) with inhomogeneity of the intralesional signal and thick contrast-enhanced wall (Fig. 1, panel C), whereas PET/CT identified only a rim of slight FDG uptake with a maximum standardized uptake value (SUVmax) equal to 3.51 (Fig. 1, panel D and E).

These findings were more consistent with the diagnosis of an inflammatory/infected fluid collection arising from the pancreas.

Treatment

CT-guided drainage of the lesion showed a brownish-green fluid with high content of pancreatic enzymes at laboratory examination (amylase: 2548 U/L), consistent with a necrotic collection after acute pancreatitis with involvement of the left adrenal gland and left kidney.

Outcome and follow-up

After the intervention, the size of the mass was reduced in CT images and a drainage tube was positioned in the fluid collection (Fig. 1, panel F). A few days later, there was no drain production from the tube; hence, it was removed, and the patient was discharged from the hospital. The patient showed a complete resolution of the abdominal pain at the follow-up examination 3 months later. An MRI confirmed that there were no remnants in the adrenal lodge. Adrenal function, normal before the procedures, was not impaired also 4 months after.

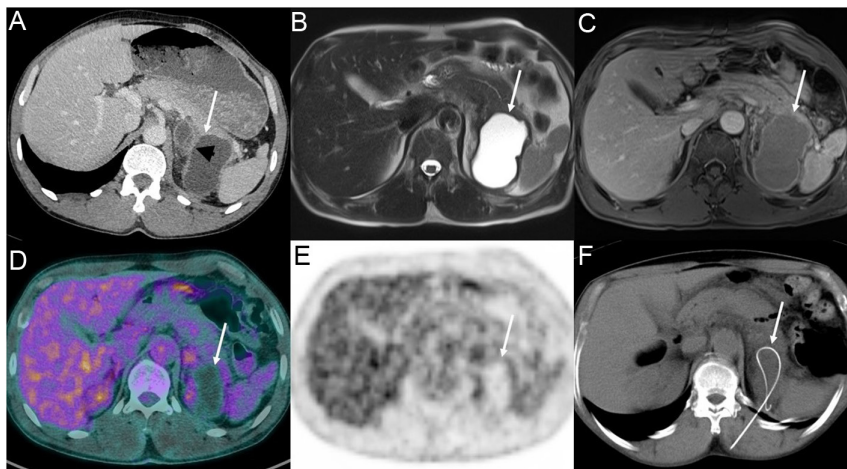


Figure 1

Images of the pancreatic cyst. Panel (A): contrast-enhanced CT of the solid-cystic mass in the left adrenal lodge; panel (B and C): MRI examination showed a large liquid lesion at images; panel (D): PET/CT with mild glucose uptake; panel (F): drainage tube.



Discussion

Acute pancreatitis is caused by the activation and inappropriate release of pancreatic digestive enzymes within the pancreatic acini with a consequent autodigestion of the parenchyma (1). There are several causes of this dysregulation of the exocrine enzymatic cascade of the pancreas: gallstone, alcohol consumption, hypertriglyceridemia, familial pancreatitis, viral infections, obstruction of the pancreatic ducts, congenital malformation (such as *pancreas divisum*), adverse event after endoscopic retrograde cholangiopancreatography or drug-related (more than 500 medications showed at least a correlation with acute pancreatitis) (1, 2). Acute pancreatitis can be differentiated into interstitial edematous pancreatitis, characterized by edema and inflammation of the pancreatic and peripancreatic tissues, and necrotizing pancreatitis, in which the inflammatory process causes necrosis of pancreatic/peripancreatic tissue (1, 3). The latter within 4 weeks from the beginning of the disease may show the presence of acute necrotic collections which could be intra- or extra-pancreatic (1, 3). These necrotic collections at conventional imaging (CT and MRI) are inhomogeneous fluid collections containing solid tissue which could become walled-off necrosis with thick contrast-enhanced walls (4).

18-FDG PET/CT has been reported to differentiate autoimmune pancreatitis from pancreatic cancer, either for the uptake distribution or the different SUVmax of the two entities (5). In the case of a necrotic collection, there will be absent FDG uptake in the area of necrosis due to the lack of vital tissue (6, 7).

The multidisciplinary approach is an emerging model of treatment; recent acquisitions (cancer biology, diagnostic procedures and molecular-target therapies) have increased the complexity of the decisional process. Multidisciplinary teams are used by several healthcare providers before achieving their evidence (8). In the described case, the lesion on CT images did not show contrast enhancement even if it had mean densitometry >10 HU, on MRI images it was clearly liquid and there was no FDG uptake inside the lesion at PET/CT. These findings allowed us to rule out a malignant behavior of the mass and MRI proved to be more useful than CT in the characterization of this complex lesion that was found in the adrenal lodge. Moreover, thanks to the multidisciplinary discussion, the imaging and clinical data could be evaluated together by the specialists, in order to make a correct and prompt diagnosis (without the need for biopsy confirmation). Indeed, the presence of a proteinaceous/hemorrhagic

content of the lesion (mean densitometry >10 HU and inhomogeneity of the intralesional signal) jointly with the involvement of the pancreas, the presence of pain in that area and the slight increase in the serum amylase allowed to rise the hypothesis of an inflammatory process of the pancreas, such as focal pancreatitis. We have no sufficient data to propose a conclusive diagnosis; however, according to the case presentation, the most suitable final diagnosis can be viral focal pancreatitis (9), after the exclusion of another painless pancreatitis (especially the autoimmune form).

Declaration of interest

The authors declare that there is no conflict of interest that could be perceived as prejudicing the impartiality of the research reported.

Funding

This work did not receive any specific grant from any funding agency in the public, commercial, or not-for-profit sector.

Patient consent

Written informed consent for publication of their clinical details and/or clinical images was obtained from the patient and is available for reviewers.

Author contribution statement

F Cr, G B and L E collected and analyzed the data and drafted the manuscript. I T contributed to study design and reviewed/edited the manuscript. F Ce conceived the study design, contributed to the data analysis and reviewed/edited the manuscript.

References

- 1 Mederos MA, Reber HA & Girgis MD. Acute pancreatitis: a review. *JAMA* 2021 **325** 382–390. (<https://doi.org/10.1001/jama.2020.20317>)
- 2 Zilio MB, Eyff TF, Azeredo-Da-Silva ALF, Bersch VP & Osvaldt AB. A systematic review and meta-analysis of the aetiology of acute pancreatitis. *HPB* 2019 **21** 259–267. (<https://doi.org/10.1016/j.hpb.2018.08.003>)
- 3 Banks PA, Bollen TL, Dervenis C, Gooszen HG, Johnson CD, Sarr MG, Tsiotos GG, Vege SS & Acute Pancreatitis Classification Working Group. Classification of acute pancreatitis – 2012: revision of the Atlanta classification and definitions by international consensus. *Gut* 2013 **62** 102–111. (<https://doi.org/10.1136/gutjnl-2012-302779>)
- 4 Bastati N, Kristic A, Poetter-Lang S, Messner A, Herold A, Hodge JC, Schindl M & Ba-Ssalamah A. Imaging of inflammatory disease of the pancreas. *British Journal of Radiology* 2021 **94** 20201214. (<https://doi.org/10.1259/bjr.20201214>)
- 5 Zhang J, Jia G, Zuo C, Jia N & Wang H. 18F-FDG PET/CT helps differentiate autoimmune pancreatitis from pancreatic cancer. *BMC Cancer* 2017 **17** 695. (<https://doi.org/10.1186/s12885-017-3665-y>)
- 6 Kahle XU, Montes de Jesus FM, Kwee TC, van Meerten T, Diepstra A, Rosati S, Glaudemans AWJM, Noordzij W, Plattel WJ & Nijland M. Relationship between semiquantitative 18F-fluorodeoxyglucose



positron emission tomography metrics and necrosis in classical Hodgkin lymphoma. *Scientific Reports* 2019 **9** 11073. (<https://doi.org/10.1038/s41598-019-47453-5>)

7 Kahle XU, Hovingh M, Noordzij W, Seitz A, Diepstra A, Visser L, van den Berg A, van Meerten T, Huls G, Boellaard R, *et al.* Tumour necrosis as assessed with (18)F-FDG PET is a potential prognostic marker in diffuse large B cell lymphoma independent of MYC rearrangements. *European Radiology* 2019 **29** 6018–6028. (<https://doi.org/10.1007/s00330-019-06178-9>)

8 Voltan G, Boscaro M, Armanini D, Scaroni C & Ceccato F. A multidisciplinary approach to the management of adrenal incidentaloma. *Expert Review of Endocrinology and Metabolism* 2021 **16** 201–212. (<https://doi.org/10.1080/17446651.2021.1948327>)

9 Imam Z, Simons-Linares CR & Chahal P. Infectious causes of acute pancreatitis: a systematic review. *Pancreatology* 2020 **20** 1312–1322. (<https://doi.org/10.1016/j.pan.2020.08.018>)

Received in final form 1 May 2022
Accepted 12 May 2022